

Aberrant right subclavian artery at 16 to 23+6 weeks of gestation: a marker for chromosomal abnormality

Authors: Borenstein M, Minekawa R, Zidere V, Nicolaides K, Allan LD.

Harris Birthright Research Centre for Fetal Medicine, King's College Hospital, London, UK

Correspondence: Professor Lindsey Allan
Harris Birthright Research Centre for Fetal Medicine
King's College Hospital,
Denmark Hill, London SE5 8RS.
Telephone 0044 020 7346 3040 Fax 0044 020 7738 3740
lindsey.allan2@btinternet.com

Acknowledgement: This study was supported by a grant from the Fetal Medicine Foundation (Charity No: 1037116)

Running head: Aberrant right subclavian artery

This article has been accepted for publication in *Ultrasound in Obstetrics & Gynecology* and is currently being edited and typeset. Readers should note that this article has been fully refereed, but has not been through the technical editing, copy-editing and proof correction process. Wiley-Blackwell and the International Society of Ultrasound in Obstetrics and Gynecology cannot be held responsible for errors or consequences arising from the use of information contained in this article; nor do the views and opinions expressed necessarily reflect those of Wiley-Blackwell or the International Society of Ultrasound in Obstetrics and Gynecology

ABSTRACT

Objective: To determine the feasibility of defining the position of the right subclavian artery (RSA) by fetal echocardiography between 16-23 weeks of gestation, and the association between an aberrant right subclavian artery (ARSA) and chromosomal and cardiac defects.

Methods: We examined the position of the RSA in all patients who attended our unit for a fetal cardiac scan. The assessment was carried out using a transverse view of the fetal chest sweeping up from the level of the aortic arch, using color flow mapping. ARSA was diagnosed when this vessel was not seen in the normal position, and an arterial vessel was seen crossing behind the trachea towards the right arm, arising as a fourth branch of the aortic arch, at a lower level than normal.

Results: The course of the RSA could be identified in more than 95% of the 2799 fetuses examined between 16 and 23+6 weeks of gestation. An ARSA was found in 43 fetuses. The incidence was 1.5% in normal fetuses, 28.6% in trisomy 21, 18.2% in trisomy 18 and 8% in other chromosomal defects. There was an association between ARSA and cardiac defects in 7 of the 43 fetuses (16%), 3 of these 7 having a normal karyotype.

Conclusions: Assessment of the RSA by a fetal cardiologist is possible in almost all cases. The finding of ARSA is much more common in fetuses with chromosomal defects, in particular trisomy 21, where it was 29%, compared to euploid fetuses. It may also increase the incidence of additional intracardiac malformation. Examination of the position of the RSA is likely to become a routine ultrasound marker for chromosomal abnormalities in the second trimester of pregnancy.

Key words: Aberrant right subclavian artery, aortic arch, trisomy 21, second trimester screening, fetal heart

Introduction

Abnormalities of the aortic arch are fairly common malformations, occurring as variants in the normal population or alternatively occurring in association with intracardiac anomalies. One such arch abnormality is an aberrant origin of the right subclavian artery (ARSA). This artery usually arises above the level of the aortic arch, as the first branch from the innominate (or brachiocephalic) artery, which in turn is the first vessel which arises from the aortic arch (Figure 1). However, autopsy studies¹ have shown that in about 1-2% of normal people, the right subclavian artery arises anomalously as a fourth branch of the aortic arch. In contrast to the normal vessel, which arises at the level of the shoulders and travels almost horizontally rightwards, the aberrant vessel arises from the first portion of the descending aorta and passes behind the trachea and cranially as well as rightwards (Figure 2). It has been noted in autopsy series or from cardiac catheterization studies, that there is an increased incidence of this anomaly in cases of Trisomy 21, although the incidence varied between 2.8 and 100%²⁻⁸. However, there was an element of selection bias in some of these studies, in that those patients with Down's syndrome who were subjected to catheterization or autopsy were usually known to have intracardiac congenital heart disease (CHD). It should be noted that ARSA is, in general, an asymptomatic benign finding, although oesophageal compression, resulting in dysphagia, has been reported in some cases⁹⁻¹².

An aberrant RSA is not easy to identify at routine postnatal echocardiography, so the incidence of ARSA either in the normal population or in the Down's group has not been addressed recently using non-invasive technology. A study published in 2005¹³, however, described the identification of this artery during fetal echocardiography, and re-emphasised the association of an aberrant origin with trisomy 21. Two recent prenatal ultrasound studies reported an incidence of ARSA in trisomy 21 fetuses of about 28% and 37% respectively between 13 and 26 weeks of gestation¹⁴⁻¹⁵.

The aim of this study was firstly, to determine the feasibility of the prenatal assessment of the right subclavian artery during fetal echocardiography, secondly, to evaluate the association of ARSA and chromosomal abnormalities and thirdly, to evaluate the association between ARSA and cardiac defects prenatally.

Methods

The course of the right subclavian artery was sought during fetal echocardiography in all patients who attended our Unit between March 2006 (7/3/2006) and December 2007 (31/12/07). For this analysis, only singleton pregnancies between 16 and 23⁺⁶ weeks of gestation with a left aortic arch were included. All cardiac examinations were carried out by a specialist fetal cardiologist, using mainly a Voluson E8 ultrasound system (RAB 4-8-D probe, GE Medical Systems, Milwaukee, WI, USA). In order to visualize the fetal right subclavian artery, the technique previously described was followed¹⁶. A transverse view of the fetal thorax, at the level of the aortic arch, was

obtained and the arch was confirmed to cross the midline from right to left in a normal fashion; if necessary, the probe was moved to position the fetal spine at 3 or 9 o'clock, so that the subclavian artery would be either going directly up towards the transducer or directly away from it. Colour flow mapping was then used to identify the horizontal course of the right subclavian artery. The normal course of this artery is tortuous, arising from the brachiocephalic trunk and crossing the upper thorax in front of the trachea towards the right arm, at the level of the clavicles. The accompanying vein can be sometimes identified anterior to the artery (Figure 3, 4). In contrast, an ARSA arises as a fourth branch of the arch, and therefore at a lower level, close to the junction of the arterial duct with the descending aorta. Its course is diagonal and crosses the thorax posterior to the trachea, between the trachea and the spine, to reach the right arm. A wide separation can be seen between the artery and its accompanying vein, which maintains its normal position behind the clavicle (Figure 5). In some cases, pulsed Doppler of the vessel behind the trachea was used to confirm that the vessel behind the trachea was arterial, as the hemiazygous vein can, in rare cases, lie in this position.

The position of the right subclavian artery was classified as normal, aberrant or not possible to identify. Only a few minutes during the fetal echocardiogram were allocated to the classification of the course of the RSA. All data were recorded in our database with maternal demographic data and other results from fetal ultrasound examinations for subsequent analysis.

The outcomes of each pregnancy including the presence of fetal abnormalities, cardiac defect and karyotype were collected. The karyotype was obtained from a chorionic-villous or amniotic fluid sample prenatally or a blood test in a neonate with suspicious features of a chromosomal anomaly. In cases where no karyotype was obtained during fetal life, the karyotype was considered normal if the newborn appeared clinically normal to the local examining paediatrician.

Statistical analysis

Mann-Whitney U test was used to examine whether there was a significant difference in the incidence of ARSA between the chromosomally normal and abnormal fetuses.

Results

Assessment of the RSA was attempted in 2799 patients and considered successful in 2670 (95.4%).

The median gestational age was 20.3 (range 16-23.6) weeks. Fetal echocardiography was performed for the following indications: increased nuchal translucency following first trimester screening 49.9%; family history of cardiac defect 10.6%; extracardiac fetal defect 8.3%; risk reassessment following second trimester biochemistry or lack of screening for chromosomal defects 7.3%; maternal condition including diabetes, epilepsy and others 5.8%, suspected cardiac defect 5.3%, maternal medication 4.2%; abnormal second trimester ultrasound marker 2.6%; others 6%.

An ARSA was found in 43 cases out of the 2670 fetuses with successful examination. Within this group of 43 fetuses, 28 (65.1%) fetuses were chromosomally or clinically normal; 12 (27.9%) fetuses had abnormal karyotype (8 with trisomy 21, 2 with trisomy 18, 1 with monosomy chromosome x, and 1 with partial monosomy chromosome). Three (7%) fetuses were lost to follow up, but no structural abnormalities had been detected on scan. Chromosomal abnormalities were diagnosed by prenatal or postnatal karyotype or clinical assessment of the newborn. In 236 (8.8%) cases the outcome of pregnancy remains unknown due to the lack of fetal karyotype or postnatal follow up data. In table 1, the RSA assessment according to fetal karyotype or outcome is summarized.

The incidence of ARSA was significantly lower in the normal fetuses (chromosomally or known normal outcome) compared to the trisomy 21 fetuses ($p < 0.001$). Similarly, ARSA was more common in the fetuses with trisomy 18 ($p < 0.001$) and all other chromosomal abnormalities ($p = 0.002$) compared to the normal fetuses.

In the total group of 2670 patients, there was a cardiac defect found in 120 cases, 113 of whom had a normal RSA (94%). Therefore, in the group of 43 patients with ARSA, 7 (16.3%) fetuses had an intracardiac defect. Of these 7, three fetuses had a normal karyotype. In these 3, the diagnosis was tetralogy of Fallot with pulmonary atresia in two and coarctation of the aorta in one. In the 4 fetuses with a karyotype anomaly, there was an atrioventricular septal defect in one fetus with trisomy 21; a ventricular septal defect and an atrioventricular septal defect in one each of 2 fetuses with trisomy 18, and tetralogy of Fallot in one case with partial monosomy of chromosome 3. One further case of trisomy 21 proved to have a ventricular septal defect in addition to ARSA after birth.

In the 12 fetuses with ARSA and a chromosomal anomaly, 11 had one or multiple other markers of chromosomal anomaly. In one fetus however, the ARSA was the only abnormal finding.

Discussion

The findings of this study show that firstly, it is possible to assess the position of the right subclavian artery during mid-trimester fetal echocardiography with successful evaluation in more than 95% of cases. The analysis was restricted to the gestational age range of 16-23w6d in order to evaluate the usefulness of assessment of the RSA around the typical timing for routine scanning. Since the conclusion of the study, this has become part of our normal fetal echocardiogram, with an even lower failure rate. Secondly, ARSA is much more common in chromosomally abnormal than normal fetuses; and thirdly, in the karyotypically normal fetus, its presence appears to increase the risk of CHD.

The incidence of ARSA in the normal population has been reported to be about 0.5-2% in prenatal and postmortem studies^{1,4,15-17}. The results of this study confirm the findings of other smaller studies with an incidence of ARSA of 1.5% in the

chromosomally normal fetuses. In the group without karyotype confirmation, but otherwise normal, the incidence of ARSA was also about 1%.

The incidence of ARSA in the trisomy 21 population reported by pathological and postnatal studies varies between 2.8-100%²⁻⁸ and therefore the real incidence remains unclear. However, prenatal studies reported the finding of ARSA in 28-37% of affected fetuses in the second trimester of pregnancy¹³⁻¹⁵ and about 8% in the first trimester¹⁶. In our population, the incidence of ARSA was found to be 28.6% of 28 fetuses with Down's syndrome. According to our data, the presence of ARSA in the 16-23 week gestational age range, increases the risk for trisomy 21 by about 20 times, and trisomy 18 by about 12 times.

The incidence of ARSA is 1.5% in those with a normal karyotype but 3% in the group with CHD and a normal karyotype, suggesting an increased association of this finding with CHD of about double, consistent with the report of Zapata et al¹. However, the group we studied was referred for fetal echocardiography (nearly 50% for an increased nuchal translucency) and therefore at increased risk for CHD. This is evidenced by the rate of CHD of 4%, compared with the expected rate in an unselected population of about 0.6-0.8%. This may have biased this aspect of our results.

One limitation of our study is that there is no outcome in 8% of cases. In addition, there is no way of confirming our diagnosis of ARSA, or indeed a normal RSA, as the course of the RSA is not readily seen by echocardiography in postnatal life. However, an ARSA was confirmed in two of the newborns with a prenatal diagnosis of an intracardiac defect, who underwent cardiac surgery. Further tests, such as magnetic resonance imaging, which is the best method of visualizing the RSA after birth, are not justifiable in an asymptomatic newborn.

The karyotype was known to the examiner in about one third of cases coming for fetal echocardiography, so this may have introduced some bias in detection.

A further limitation is the possibility of 22q11 deletion, which was not sought in the majority of cases where there was a fetal karyotype. The Di George deletion is also a condition which may not be clinically obvious in the neonate and therefore overlooked. Although to our knowledge isolated ARSA is not a condition which is associated with 22q11 deletion, it is grouped as an "arch anomaly", some of which do have a known association with this deletion, for example, an interrupted aortic arch. One publication⁽¹⁸⁾ suggests that, at least in the setting of associated conotruncal malformations, a left arch with an aberrant left subclavian artery had a high association (85%) with 22q11 deletion.

Zalel et al¹⁵ found that all their fetuses with ARSA and chromosomal defects had other markers suggestive of chromosomal anomaly. However, one of our 12 fetuses had no other markers, so the absence of other markers cannot be relied on to exclude trisomy 21 in particular.

The advantages of our study are the large number of fetuses examined, the large number of chromosomal defects and the assessment by a specialist fetal cardiologist. Moreover, this is, to our knowledge, the largest number of cases reported to date. On the other hand, this is a highly selected group examined by specialists. We believe that the examination of the position of RSA is not difficult for the fetal cardiologist and is fairly easy for sonographers with experience in the evaluation of the fetal heart. However, the results given here may be difficult to reproduce in a screening setting and certainly will require a period of training for those less skilled in fetal cardiac scanning.

We have now incorporated the assessment of RSA into our routine examination, and in the presence of an isolated ARSA we discuss the option of an invasive test with the parents. Data on the position of the RSA in an unselected low risk population is not yet available; however we believe that if such studies confirm our findings, the assessment of the position of the right subclavian artery may become a useful marker for chromosomal defects, especially if used in combination with other ultrasound markers.

Acknowledgements

We are grateful for the contribution of Paolo Cavoretto, Nicola Persico, and Ian Huggon with data collection and to Laura Lloyd for gathering follow-up data.

References

1. Zapata H, Edwards JE, Titus JL. Aberrant right subclavian artery with left aortic arch: associated cardiac anomalies. *Pediatr Cardiol* 1993;14:159-61.
2. Evans PR. Cardiac anomalies in Mongolism. *Br Heart J* 1950;12:258-62.
3. Strauss I. Congenital cardiac anomalies with mongolism. *Trans Am Coll Cardiol* 1953;3:214-21.
4. Molz G, Burri B. Aberrant subclavian artery (arteria lusoria): sex differences in the prevalence of various forms of the malformation. *Virchows Arch A Path Anat and Histol* 1978;380:303-15.
5. Rowe RD, Uchida IA. Cardiac malformation in mongolism: a prospective study of 184 mongoloid children. *Am J Med* 1961; 31:726-9.
6. Goldstein WB. Aberrant right subclavian artery in Mongolism. *Am J Roentgenol* 1965; 95:131-4.
7. Lo RNS, Leung PM, Lau KC, Yeung CY. Congenital cardiovascular malformations in Chinese children with Down's syndrome. *Chin Med J* 1989;102:382-6.
8. Rathore MH, Sreenivasan VV. Vertebral and right subclavian artery abnormalities in the Down syndrome. *Am J Cardiol* 1989;63:1528-9.
9. Janssen M, Baggen MG, Veen HF, Smout AJ, Bekkers JA, Jonkman JG, Ouwendijk RJ. Dysphagia lusoria: clinical aspects, manometric findings, diagnosis, and therapy. *Am J Gastroenterol.* 2000;95:1411-6.
10. Kent PD, Poterucha TH. Images in clinical medicine. Aberrant right subclavian artery and dysphagia lusoria. *N Engl J Med.* 2002;347:1636.
11. Yopp A, Abrol S, Cunningham J, Lazzaro R. Dysphagia Lusoria and Aberrant Right Subclavian Artery. *J Am Col Surg* 2006;202:198.

12. Bickston S, Guarino P, Chowdhry S. Education and imaging. Gastrointestinal: dysphagia lusoria. *J Gastroenterol Hepatol.* 2008;23:989.
13. Chaoui R, Heiling KS, Sarioglu N, Schwabe M, Dankof A, Bollmann R. Aberrant right subclavian artery as a new cardiac sign in second-and third-trimester fetuses with Down syndrome. *Am J Obstet Gynecol* 2005;192:257-63.
14. Chaoui R, Thiel G, Heling KS. Prevalence of an aberrant right subclavian artery (ARSA) in fetuses with chromosomal aberrations. *Ultrasound Obstet Gynecol* 2006;28:414.
15. Zalel Y, Achiron R, Yagel S, Kivilevitch Z. Fetal aberrant right subclavian artery in normal fetuses and in Down syndrome. *Ultrasound Obstet Gynecol* 2007;30:398.
16. Borenstein M, Cavoretto P, Allan L, Huggon I, Nicolaidis KH. Aberrant right subclavian artery at 11-13+6 weeks of gestation in chromosomally normal and chromosomally abnormal fetuses. *Ultrasound Obstet Gynecol* 2008;31:20-4.
17. Chaoui R, Thiel G, Heling KS. Prevalence of an aberrant right subclavian artery (ARSA) in normal fetuses: a new soft marker for trisomy 21 risk assessment. *Ultrasound Obstet Gynecol* 2005;26:356.
18. Rauch R, Rauch A, Koch A, Zink S, Kaulitz R, Girisch M, Singer H, Hofbeck M. Laterality of the aortic arch and anomalies of the subclavian artery-reliable indicators for 22q11.2 deletion syndromes? *Eur J Pediatr.* 2004;163:642-5.

Table 1. Outcome of pregnancy and position of the right subclavian artery in the fetuses with successful assessment. (N=number of cases)

| Outcome | N | Right subclavian artery n (%) | |
|----------------------------|------|-------------------------------|------------|
| | | Normal | Aberrant |
| Normal karyotype | 932 | 918 (98.5%) | 14 (1.5%) |
| Normal clinical assessment | 1438 | 1424 (99.3%) | 14 (0.97%) |
| Trisomy 21 | 28 | 20 (71.4%) | 8 (28.6%) |
| Trisomy 18 | 11 | 9 (81.8%) | 2 (18.2%) |
| Other chromosomal defects | 25 | 23 (92%) | 2 (8%) |
| No follow up data | 236 | 233 (98.7%) | 3 (1.2%) |
| Total | 2670 | 2627 | 43 |

Figure 1. Postnatal MRI demonstrates normal origin of the left (LSA) and right subclavian arteries (RSA), Ao=aorta.

Figure 2. Postnatal MRI demonstrates an aberrant right subclavian artery (ARSA) arising from the descending aorta. Note that the course of an ARSA would not be seen in a standard long-axis view of the aortic arch.

Figure 3. Tomographic images demonstrate the relationship of the normal right subclavian artery to the standard views. Note that the normal right subclavian artery lies 3mm above the level of the transverse arch and 15.8mm above the four-chamber view in this 20 week fetus. RV=right ventricle, T=trachea, Ao=aorta, MPA= main pulmonary artery, RSA=right subclavian artery

Figure 4. Just above the level of the aortic arch, the right and left subclavian arteries are seen in their normal position on colour flow mapping. In order to distinguish the arteries from the arm veins, which run close to each other, the colour map must be as expected, with flow away from the aortic arch in both vessels. Also a long course of vessel extending outside the confines of the thorax must be seen, which will ensure distinction from the branch pulmonary arteries which lie just below the arch. Abbreviations, same as above and LSV=left subclavian vein

Figure 5. An aberrant right subclavian artery arises from the descending aorta behind the trachea and below the level of the aortic arch at the level of the arterial duct, in contrast to the normal right subclavian which arises above the arch.

Figure 1

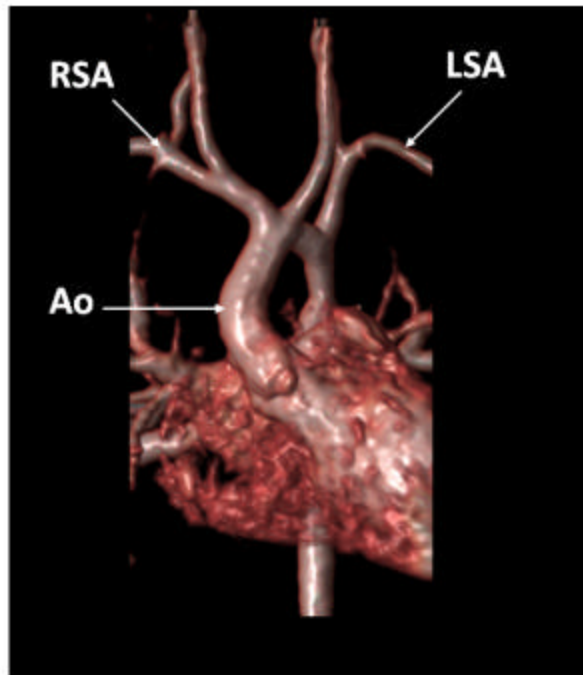


Figure 1. Postnatal MRI demonstrates normal origin of the left (LSA) and right subclavian arteries (RSA), Ao=aorta.

Figure 2

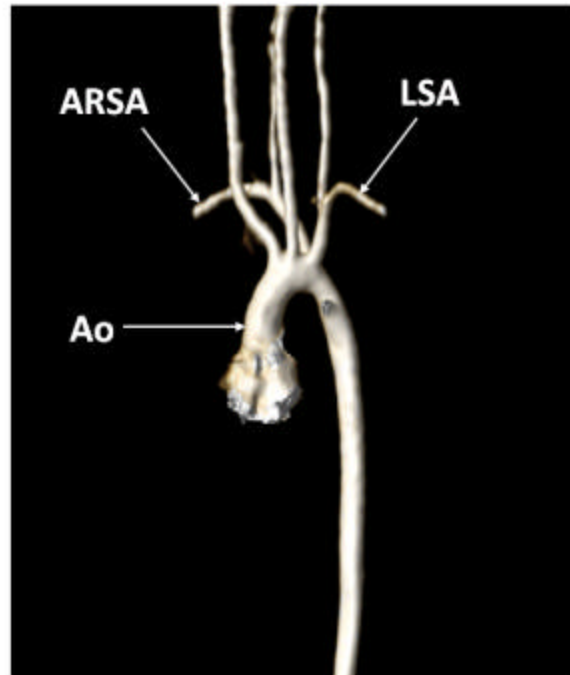


Figure 2. Postnatal MRI demonstrates an aberrant right subclavian artery (ARSA) arising from the descending aorta. Note that the course of an ARSA would not be seen in a standard long-axis view of the aortic arch.

Figure 4

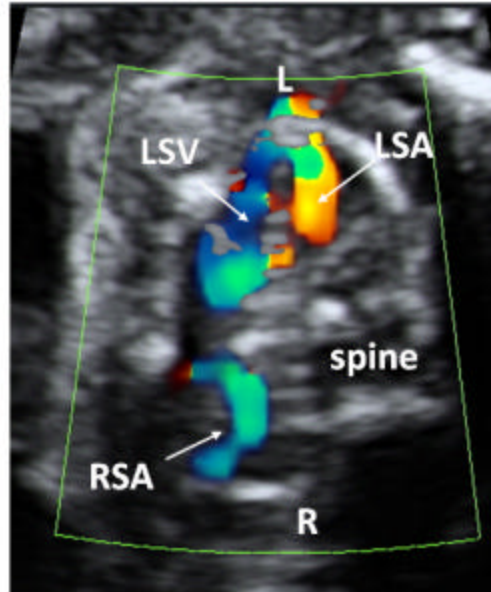


Figure 4. Just above the level of the aortic arch, the right and left subclavian arteries are seen in their normal position on colour flow mapping. In order to distinguish the arteries from the arm veins, which run close to each other, the colour map must be as expected, with flow away from the aortic arch in both vessels. Also a long course of vessel extending outside the confines of the thorax must be seen, which will ensure distinction from the branch pulmonary arteries which lie just below the arch. Abbreviations, same as above and LSV=left subclavian vein

Figure 5

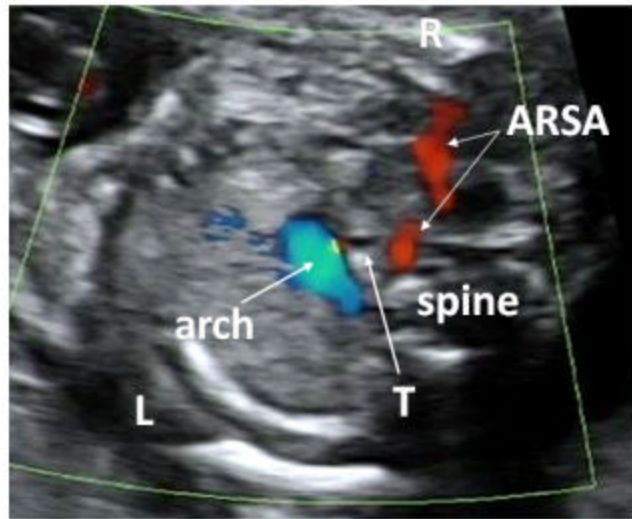


Figure 5. An aberrant right subclavian artery arises from the descending aorta behind the trachea and below the level of the aortic arch at the level of the arterial duct, in contrast to the normal right subclavian which arises above the arch.