

Choroid plexus cyst, intracardiac echogenic focus, hyperechogenic bowel and hydronephrosis in screening for trisomy 21 at 11 + 0 to 13 + 6 weeks

T. DAGKLIS, W. PLASENCIA, N. MAIZ, L. DUARTE and K. H. NICOLAIDES

Harris Birthright Research Centre for Fetal Medicine, King's College Hospital, London, UK

KEYWORDS: cardiac echogenic focus; choroid plexus cysts; echogenic bowel; first-trimester screening; hydronephrosis; trisomy 21

ABSTRACT

Objectives To investigate the potential value of choroid plexus cyst, intracardiac echogenic focus, hydronephrosis and hyperechogenic bowel as markers of trisomy 21 at 11 + 0 to 13 + 6 weeks.

Methods We examined three-dimensional volumes from 228 fetuses with trisomy 21 and 797 chromosomally normal fetuses at 11 + 0 to 13 + 6 weeks of gestation. We looked for choroid plexus cysts with a minimum diameter of 1.5 mm, intracardiac echogenic focus, hydronephrosis with a minimum anteroposterior diameter of the pelvis of 1.5 mm and hyperechogenic bowel.

Results The prevalence of intracardiac echogenic focus, hydronephrosis and hyperechogenic bowel was significantly higher in trisomy 21 than in normal fetuses (9.6% vs. 1.5%, 17.1% vs. 5.3% and 11.4% vs. 2.4%, respectively). There was no significant difference between the two groups in the prevalence of choroid plexus cysts (7.5% vs. 5.0%). There were no significant differences in crown–rump length or nuchal translucency thickness in either chromosomally normal or trisomy 21 fetuses between those with and those without any one of the markers.

Conclusions At 11 + 0 to 13 + 6 weeks the prevalence of intracardiac echogenic focus, hydronephrosis and hyperechogenic bowel is higher in trisomy 21 than in chromosomally normal fetuses. As there is no significant association between the presence of these markers and nuchal translucency thickness, they could be included in the assessment of risk to improve accuracy of screening. Copyright © 2007 ISUOG. Published by John Wiley & Sons, Ltd.

INTRODUCTION

Sonographic markers of trisomy 21 in the second trimester of pregnancy include increased nuchal fold thickness, nasal hypoplasia, shortening of the limbs, intracardiac echogenic foci, choroid plexus cysts, hydronephrosis and hyperechogenic bowel^{1,2}. In the first trimester the main emphasis of ultrasound screening has centered around increased nuchal translucency (NT) thickness and more recently on absent or hypoplastic nasal bone^{2–4}. A study investigating the length of the femur and humerus reported that, although the mean values in trisomy 21 fetuses are shorter than those in normal fetuses, the degree of deviation from normal is too small for these measurements to be useful in screening⁵. Another study of 16 fetuses with trisomy 21 reported that one of the fetuses had an intracardiac echogenic focus, and another had hydronephrosis and choroid plexus cysts⁶.

This study of 228 fetuses with trisomy 21 examines the potential value of choroid plexus cysts, intracardiac echogenic foci, hydronephrosis and hyperechogenic bowel as markers of this chromosomal abnormality at 11 + 0 to 13 + 6 weeks.

METHODS

Two populations of singleton pregnancies at 11 + 0 to 13 + 6 weeks of gestation were examined. The first (Group A) comprised 500 consecutive self-referred women attending the Fetal Medicine Centre, London for routine first-trimester screening for trisomy 21 by a combination of fetal NT and maternal serum free beta-human chorionic gonadotropin (β -hCG) and pregnancy-associated plasma protein-A (PAPP-A)⁴. Patient-specific risks for trisomy 21 were calculated by a multivariate

Correspondence to: Prof. K. H. Nicolaides, Harris Birthright Research Centre for Fetal Medicine, King's College Hospital Medical School, Denmark Hill, London SE5 8RX, UK (e-mail: fmf@fetalmedicine.com)

Accepted: 20 August 2007

approach. Essentially, the maternal age-related risk was multiplied with each likelihood ratio derived from the fetal delta NT (difference of observed NT from the normal mean for crown-rump length (CRL)) and maternal weight-adjusted serum free β -hCG and PAPP-A. The minimum and maximum likelihood ratios allowed were 0.185 and 509 for NT, 0.014 and 62 for each of free β -hCG and PAPP-A, and 0.05 and 1000 for the combined sonographic and biochemical markers.

The second population (Group B) were women who chose to have chorionic villus sampling for fetal karyotyping following first-trimester combined screening for trisomy 21. Of these, we selected 225 cases in which the fetal karyotype was subsequently found to be trisomy 21 and 300 consecutive cases with a normal karyotype.

In both groups of women a three-dimensional (3D) volume of the fetus in the mid-sagittal position was acquired by transabdominal sonography (RAB 4-8L probe, Voluson 730 Expert, GE Medical Systems, Milwaukee, WI, USA) routinely either during the scan at 11 + 0 to 13 + 6 weeks or immediately before chorionic villus sampling in those undergoing this procedure.

Two sonographers with extensive experience in 3D ultrasound imaging examined each of the 1025 fetal volumes (500 from Group A and 525 from Group B) without prior knowledge of either the group or the fetal karyotype. The 3D volumes were displayed in the three orthogonal planes that compose the multiplanar mode of the 3D image, and the appropriate planes were examined for the diagnosis of choroid plexus cyst, intracardiac echogenic focus, hydronephrosis and hyperechogenic bowel (Figure 1). First, a transverse plane of the fetal head was selected, as for measurement of the biparietal diameter, and both choroid plexuses were examined systematically from their lower to their upper limit for the presence of cystic structures through a series of transverse sections. The internal diameter of any obvious cyst was measured. Second, a transverse plane through the thorax was obtained to display the apical four-chamber view of the heart and both ventricles were examined systematically from their lower to their upper limit for the presence of an intracardiac echogenic focus through a series of transverse sections. Third, a transverse plane through the upper abdomen was obtained to display

the kidneys and the anteroposterior diameter of each renal pelvis was measured. The bowel was examined in a series of transverse and longitudinal sections through the lower abdomen, and considered to be hyperechogenic if of similar echogenicity to that of the adjacent iliac bone.

Statistical analysis

In the 500 cases of Group A an obvious choroid plexus cyst was observed in 45 cases and the diameter was 1–3 mm. In 25 cases (5.0% of the total) the diameter was 1.5 mm or more and this cut-off was used to define the presence of a choroid plexus cyst. Similarly, a measurable renal pelvis was observed in 420 of the 500 cases and the anteroposterior diameter was 0.6–2.5 mm. In 26 cases (5.2% of the total) the diameter was 1.5 mm or more and this cut-off was used to define the presence of hydronephrosis. The prevalence of each sonographic marker was determined in the chromosomally normal and trisomy 21 cases, and logistic regression was performed to examine whether the differences were significant. Independent-samples *t*-test was used to examine the significance of differences in mean CRL and mean delta-NT between fetuses with and without each of the markers in both the chromosomally normal and trisomy 21 fetuses. Data were analyzed using the statistical software SPSS 12.0 (Chicago, Illinois, USA) and Excel for Windows 2003 (Microsoft Corp., Redmond, WA, USA). $P < 0.05$ was considered statistically significant.

RESULTS

In the 500 women undergoing first-trimester combined screening (Group A) the median maternal age was 36 (range, 24–45) years and the median gestation was 12 (range, 11 + 0 to 13 + 6) weeks. The median estimated risk for trisomy 21 following combined screening was one in 3665 (range, one in two to one in 20 040) and the expected total number of trisomy 21 fetuses was 2.9. In 26 cases with an estimated risk greater than one in 300, chorionic villus sampling was carried out; in three cases the karyotype was trisomy 21 and in 23 it was normal. In the 474 cases with an estimated risk of less than one in 300, the median risk was one in 3880 and

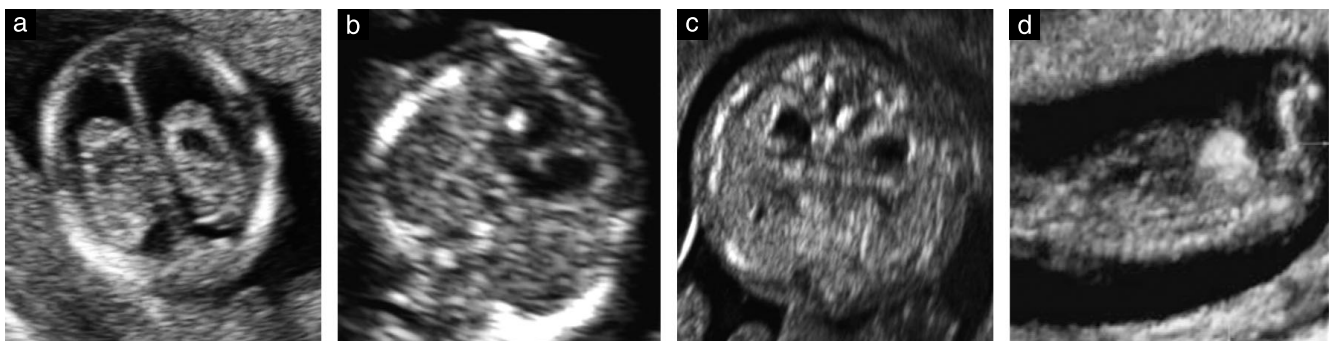


Figure 1 Ultrasound images demonstrating choroid plexus cyst (a), intracardiac echogenic focus (b), hydronephrosis (c) and hyperechogenic bowel (d) at 12 weeks of gestation.

the expected total number of trisomy 21 fetuses was 0.2; it was assumed that these fetuses were chromosomally normal. The prevalence of each sonographic marker in the presumed chromosomally normal group of 497 cases and in the three with trisomy 21 is shown in Table 1.

In 525 women who chose to have chorionic villus sampling for fetal karyotyping following first-trimester combined screening for trisomy 21 (Group B) the median gestation was 12 (range, 11 + 0 to 13 + 6) weeks. The median maternal age was 37 (range, 20–46) years in those with trisomy 21 fetuses and 35 (range, 17–47) years in those whose fetus had a normal karyotype. The prevalence of each sonographic marker in the chromosomally normal group and in those with trisomy 21 is shown in Table 1.

The data for the combined group of 797 normal fetuses (497 from Group A and 300 from Group B) and the 228 fetuses with trisomy 21 (three from Group A and 225 from Group B) are shown in Table 1. There was a significantly higher prevalence of intracardiac echogenic focus (9.6% vs. 1.5%, $P < 0.001$), hydronephrosis (17.1% vs. 5.3%, $P < 0.001$) and hyperechogenic bowel (11.4% vs. 2.4%, $P < 0.001$) in the trisomy 21 fetuses compared with the normal fetuses. There was no significant difference between the two groups in the prevalence of choroid plexus cysts (7.5% vs. 5.0%, $P = 0.157$). There were no significant differences in CRL or NT thickness in either chromosomally normal or trisomy 21 fetuses between those with and those without any one of the markers (Table 2). An intracardiac echogenic focus, or hydronephrosis or hyperechogenic bowel was observed in 75 (32.9%) of the 228 fetuses with trisomy 21 and in 66 (8.3%) of 797 normal fetuses.

DISCUSSION

This study has demonstrated the feasibility of assessing the traditional second-trimester markers of trisomy 21 at 11 + 0 to 13 + 6 weeks. In the first trimester the prevalence of intracardiac echogenic focus, hydronephrosis and hyperechogenic bowel was higher in trisomy 21 than in chromosomally normal fetuses, and this was unrelated to CRL or NT thickness. The prevalence of choroid plexus cysts was not significantly different between the trisomy 21 and normal fetuses.

In the second trimester of pregnancy there is a wide range in the reported prevalence of sonographic markers

in normal and trisomy 21 fetuses¹. Hydronephrosis is defined by the finding of a minimum anteroposterior diameter of the pelvis of 4.0 mm at 15–19 weeks and 5.0 mm at 20–29 weeks⁷. The prevalence of hydronephrosis is 1–3% in normal fetuses and 10–25% in trisomy 21 fetuses^{1,8,9}. Similarly, hyperechogenic bowel is reported in 1–3% of normal fetuses and in 10–25% of trisomy 21 fetuses^{1,9}. Intracardiac echogenic foci are found in 4–7% of normal fetuses and in 15–30% of trisomy 21 fetuses^{1,9,10}. Consequently, the prevalence of these markers in both the first and second trimesters is higher in trisomy 21 than in normal fetuses.

In the second trimester choroid plexus cysts are found in 1–3% of normal fetuses and in 30–50% of trisomy 21 fetuses^{1,12–14}. The prevalence of choroid plexus cysts in trisomy 21 fetuses is uncertain because the number of reported cases is small and the studies have varied between those attempting to report on the prevalence as an isolated finding or multiple defects¹. A meta-analysis of fetuses with isolated choroid plexus cysts reported that the likelihood of trisomy 21 was not significantly greater than the *a priori* risk¹⁵. However, in the presence of additional defects the prevalence of choroid plexus cysts was 6–20% in trisomy 21 fetuses and 1–2% in normal fetuses¹. In our first-trimester study there was no significant difference in the prevalence of choroid plexus cysts between trisomy 21 and normal fetuses.

The findings on the prevalence of hydronephrosis and hyperechogenic bowel at 11 + 0 to 13 + 6 weeks are compatible with those in the second trimester. However, the prevalence of intracardiac echogenic foci in both trisomic and normal fetuses at 11 + 0 to 13 + 6 weeks is two to three times lower than that in the second trimester. Consequently, the incidence and/or size of these lesions increase between around 12 and 16 weeks of gestation. A previous study reported that the prevalence of echogenic foci does not increase with gestation between 16 and 24 weeks¹¹.

At 11 + 0 to 13 + 6 weeks an intracardiac echogenic focus, or hydronephrosis or hyperechogenic bowel was observed in 32.9% of fetuses with trisomy 21 and in 8.3% of normal fetuses. Consequently, first-trimester screening using these sonographic markers would be associated with a substantially lower detection rate and higher false-positive rate than with screening by fetal NT thickness

Table 1 Prevalence and likelihood ratios of choroid plexus cyst, intracardiac echogenic focus, hydronephrosis and hyperechogenic bowel in normal and trisomy 21 fetuses in the screened population (Group A) and in patients undergoing chorionic villus sampling (Group B)

Ultrasound marker	Group A (n (%))		Group B (n (%))		Combined A and B (n (%))		Likelihood ratio (95% CI)
	Normal (n = 497)	Trisomy 21 (n = 3)	Normal (n = 300)	Trisomy 21 (n = 225)	Normal (n = 797)	Trisomy 21 (n = 228)	
Choroid plexus cyst	24 (4.8)	1 (33.3)	16 (5.3)	16 (7.1)	40 (5.0)	17 (7.5)	1.49 (0.85–2.57)
Intracardiac echogenic focus	8 (1.6)	1 (33.3)	4 (1.3)	21 (9.3)	12 (1.5)	22 (9.6)*	6.41 (3.22–12.75)
Hydronephrosis	26 (5.2)	–	16 (5.3)	39 (17.3)	42 (5.3)	39 (17.1)*	3.25 (2.15–4.89)
Hyperechogenic bowel	12 (2.4)	–	7 (2.3)	26 (11.5)	19 (2.4)	26 (11.4)*	4.78 (2.70–8.48)

*Significantly higher prevalence in trisomy 21 fetuses than in normal fetuses.

Table 2 Differences in mean crown–rump length and mean delta nuchal translucency between fetuses with and without each of the markers in the chromosomally normal and trisomy 21 fetuses

Ultrasound marker	Normal (n = 797)		Trisomy 21 (n = 228)	
	Mean difference in mm (95% CI)	P	Mean difference in mm (95% CI)	P
Crown–rump length				
Choroid plexus cyst	2.75 (–0.10 to 5.60)	0.058	1.06 (–2.83 to 4.96)	0.591
Intracardiac echogenic focus	4.60 (–0.51 to 9.71)	0.078	2.31 (–1.14 to 5.76)	0.189
Hydronephrosis	1.65 (–1.13 to 4.44)	0.245	1.69 (–1.01 to 4.40)	0.219
Hyperechogenic bowel	–0.04 (–4.13 to 4.04)	0.984	1.16 (–2.05 to 4.38)	0.477
Delta nuchal translucency				
Choroid plexus cyst	0.158 (–0.104 to 0.420)	0.236	–0.862 (–1.766 to 0.402)	0.216
Intracardiac echogenic focus	–0.001 (–0.471 to 0.469)	0.997	–0.104 (–1.072 to 0.863)	0.832
Hydronephrosis	0.025 (–0.231 to 0.280)	0.849	0.005 (–0.753 to 0.764)	0.989
Hyperechogenic bowel	0.130 (–0.245 to 0.504)	0.497	0.366 (–0.531 to 1.264)	0.422

and maternal serum free β -hCG and PAPP-A, in which the detection rate is about 90% for a false-positive rate of 5%^{16,17}. However, the diagnosis of an echogenic focus, hydronephrosis or hyperechogenic bowel can be made easily during the routine examination of fetal anatomy in the first trimester and, as there is no significant association between the presence of these markers and NT thickness, they could be included in the assessment of risk to improve the accuracy of screening.

ACKNOWLEDGMENTS

This study was supported by a grant from The Fetal Medicine Foundation (charity number 1037116).

REFERENCES

- Smith-Bindman R, Hosmer W, Feldstein V, Deeks J, Goldberg J. Second-trimester ultrasound to detect fetuses with Down syndrome: a meta-analysis. *JAMA* 2001; **285**: 1044–1055.
- Sonek JD, Cicero S, Neiger R, Nicolaides KH. Nasal bone assessment in prenatal screening for trisomy 21. *Am J Obstet Gynecol* 2006; **195**: 1219–1230.
- Snijders RJM, Noble P, Sebire N, Souka A, Nicolaides KH. UK multicentre project on assessment of risk of trisomy 21 by maternal age and fetal nuchal translucency thickness at 10–14 weeks of gestation. *Lancet* 1998; **351**: 343–346.
- Nicolaides KH. Nuchal translucency and other first-trimester sonographic markers of chromosomal abnormalities. *Am J Obstet Gynecol* 2004; **191**: 45–67.
- Longo D, DeFigueiredo D, Cicero S, Sacchini C, Nicolaides KH. Femur and humerus length in trisomy 21 fetuses at 11–14 weeks of gestation. *Ultrasound Obstet Gynecol* 2004; **23**: 143–147.
- Whitlow BJ, Lazanakis ML, Kadir RA, Chatzipapas I, Economides DL. The significance of choroid plexus cysts, echogenic heart foci and renal pyelectasis in the first trimester. *Ultrasound Obstet Gynecol* 1998; **12**: 385–390.
- Benacerraf BR, Mandell J, Estroff JA, Harlow BL, Frigoletto FD Jr. Fetal pyelectasis: a possible association with Down syndrome. *Obstet Gynecol* 1990; **76**: 58–60.
- Coco C, Jeanty P. Isolated fetal pyelectasis and chromosomal abnormalities. *Am J Obstet Gynecol* 2005; **193**: 732–738.
- Nicolaides KH. Screening for chromosomal defects. *Ultrasound Obstet Gynecol* 2003; **21**: 313–321.
- Coco C, Jeanty P, Jeanty C. An isolated echogenic heart focus is not an indication for amniocentesis in 12 672 patients. *J Ultrasound Med* 2004; **23**: 489–496.
- Lim L, Aptekar L, Bombard A, Juliard K, Meenakshi B, Weiner Z. Ethnicity and other factors that may affect the prevalence of echogenic intracardiac foci in the fetus. *J Clin Ultrasound* 2006; **34**: 327–329.
- Thorpe-Beeston JG, Gosden CM, Nicolaides KH. Choroid plexus cysts and chromosomal defects. *Br J Radiol* 1990; **63**: 783–786.
- Snijders RJ, Shawa L, Nicolaides KH. Fetal choroid plexus cysts and trisomy 18: assessment of risk based on ultrasound findings and maternal age. *Prenat Diagn* 1994; **14**: 1119–1127.
- Coco C, Jeanty P. Karyotyping of fetuses with isolated choroid plexus cysts is not justified in an unselected population. *J Ultrasound Med* 2004; **23**: 899–906.
- Yoder PR, Sabbagha RE, Gross SJ, Zelop CM. The second-trimester fetus with isolated choroid plexus cysts: a meta-analysis of risk of trisomies 18 and 21. *Obstet Gynecol* 1999; **93**: 869–872.
- Avgidou K, Papageorgiou A, Bindra R, Spencer K, Nicolaides KH. Prospective first-trimester screening for trisomy 21 in 30 564 pregnancies. *Am J Obstet Gynecol* 2005; **192**: 1761–1767.
- Nicolaides KH, Spencer K, Avgidou K, Faiola S, Falcon O. Multicenter study of first-trimester screening for trisomy 21 in 75 821 pregnancies: results and estimation of the potential impact of individual risk-orientated two-stage first-trimester screening. *Ultrasound Obstet Gynecol* 2005; **25**: 221–226.