

Frontomaxillary facial angle at 11 + 0 to 13 + 6 weeks: effect of plane of acquisition

W. PLASENCIA, T. DAGKLIS, C. PACHOUMI, E. KOLITSI and K. H. NICOLAIDES

Harris Birthright Research Centre for Fetal Medicine, King's College Hospital Medical School, London, UK

KEYWORDS: acquisition angle; first trimester screening; frontomaxillary facial angle; three-dimensional ultrasound

ABSTRACT

Objective To determine the range of positions of the fetal head in which a three-dimensional (3D) volume is acquired for subsequent successful assessment of the frontomaxillary facial (FMF) angle.

Method We obtained 3D volumes of the fetal head at 11 + 0 to 13 + 6 weeks. The volumes were acquired with the head in different positions and reconstructed to obtain a mid-sagittal section and demonstrate the maxilla, palate and frontal bone, which constitute the landmarks for the assessment of the FMF angle.

Results In the reconstructed mid-sagittal sections, it was possible to demonstrate the landmarks that define the FMF angle in most of the cases when the 3D volume acquisition plane was: (a) mid-sagittal, with the angle between the face of the transducer and the direction of the fetal nose being about 0–99°, 150–199° and 330–359°; (b) transverse at the level of the biparietal diameter when the angle between the transducer and the midline echo of the brain was 0–29°; and (c) oblique around the crown–rump axis when the angle from the mid-sagittal plane was 0–49°. However, the measurement of the FMF angle was artificially increased when in the mid-sagittal plane the angle was 40–99° and 150–199°.

Conclusion Successful assessment of the FMF angle by 3D ultrasound is dependent on the plane and angle of the volume acquisition. Copyright © 2007 ISUOG. Published by John Wiley & Sons, Ltd.

INTRODUCTION

In fetuses with trisomy 21 the frontomaxillary facial (FMF) angle, defined as the angle between the upper surface of the palate and the frontal bone in a mid-sagittal

view of the fetal face (Figure 1), is substantially increased¹. In a previous three-dimensional (3D) ultrasound study on 100 fetuses with trisomy 21 and 300 chromosomally normal fetuses at 11 + 0 to 13 + 6 weeks of gestation, we found that the FMF angle was above the 95th centile of the normal range in 69% of fetuses with trisomy 21¹. Consequently, measurement of the FMF angle is likely to be a useful marker, in addition to nuchal translucency thickness, in first-trimester screening for trisomy 21.

A reproducibility study on the FMF angle² demonstrated that in about 95% of cases the difference between two measurements by the same observer or measurements by different observers is within 3°. The sonographic markers of a precise mid-sagittal plane of the fetal face are the echogenic tip of the nose and the rectangular shape produced by the maxilla in the front and the palate behind². Rotation of the head away from the vertical position of the fronto-occipital diameter axis results in non-visibility of the tip of the nose, and usually at the same angle of about 10° the zygomatic process of the maxillary bone is seen at the anterior part of the maxillary palatal complex (Figure 1).

3D ultrasonography offers the potential of acquiring a volume of the fetal head in any position and then, by reconstructing the image using the multiplanar technique, it becomes possible to obtain the appropriate view for examination of the fetal profile. However, 3D ultrasound studies have shown that the ability to demonstrate the presence of the nasal bone or the corpus callosum is dependent on the plane of acquisition^{3,4}.

The aim of this study was to determine the range of positions of the fetal head in which a 3D volume is acquired for subsequent successful assessment of the FMF angle.

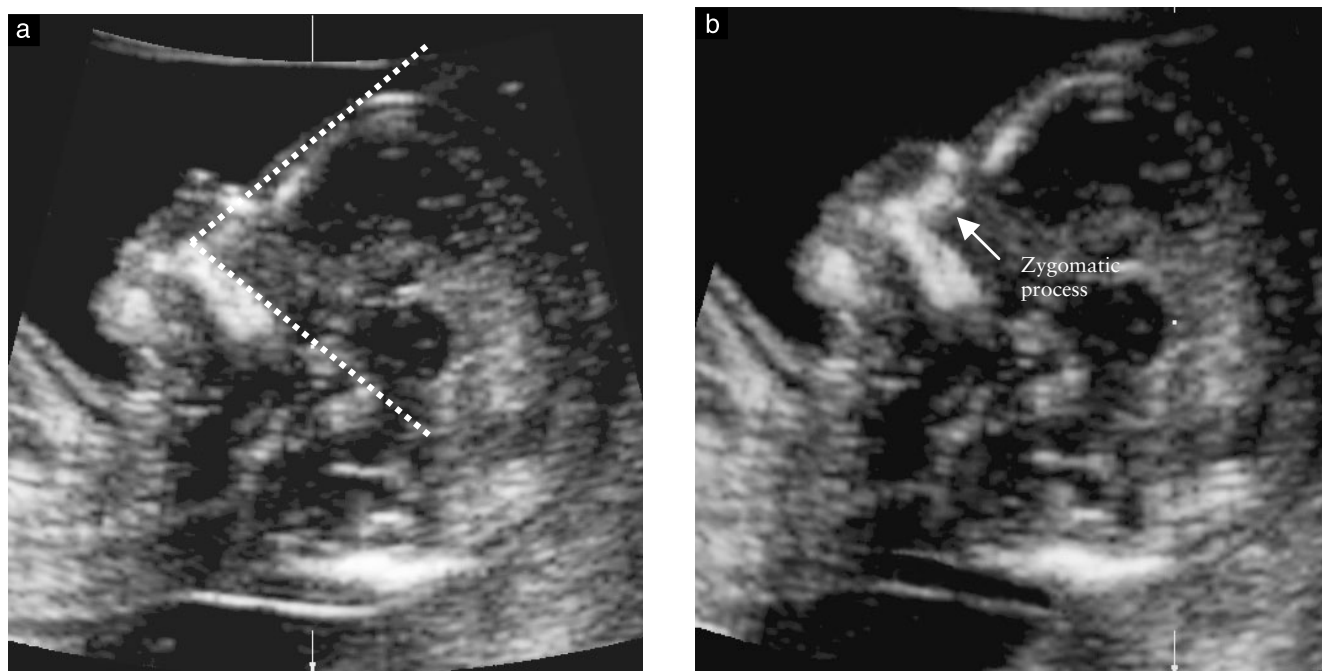


Figure 1 Ultrasound images of the fetal profile, demonstrating the measurement of the frontomaxillary facial (FMF) angle (a). After rotation by about 10° around the mid-point of the brain, the tip of the nose is visible and the rectangular shape of the maxillary palatal complex is altered by the superimposition of the zygomatic process of the maxillary bone (b).

METHODS

This was a prospective study in 103 singleton pregnancies at 11 + 0 to 13 + 6 weeks of gestation. The patients attended our unit for routine first-trimester screening for chromosomal abnormalities. In total, 465 volumes were acquired transabdominally (RAB 4-8L probe, Voluson 730 Expert, GE Medical Systems, Milwaukee, WI, USA) with the fetus at rest in the following positions of the face of the transducer in relation to the fetal head (Figure 2):

1. Mid-sagittal sections of the fetal profile with the angle between the transducer and the direction of the fetal nose in the range $0-360^\circ$.
2. Transverse sections at the level of the biparietal diameter with the angle between the transducer and the midline echo of the brain in the range $0-180^\circ$.
3. Oblique sections starting from the mid-sagittal plane of the fetal profile (0°) and rotating around the crown-rump axis to the coronal plane (90°).

The 3D volumes were then reconstructed to obtain a precise mid-sagittal plane for measurement of the FMF angle. In this image the direction of the nose is parallel to the face of the transducer (0°) and the maxilla, upper palate and forehead are clearly visible. The upper anterior corner of the maxilla constituted the apex of the FMF angle. The first arm of the angle was drawn along the upper surface of the palate. Then the external table of the frontal bone was identified and the second arm was defined as the line joining the apex with the frontal bone. In the precise mid-sagittal plane, the maxillary palatal complex had a rectangular shape. The incidence of successful demonstration of these landmarks (frontal bone

and rectangular maxillary palatal complex with clearly visible upper anterior margin), and therefore ability to measure the FMF angle, was subsequently determined for the different volume acquisition planes.

In each case the difference in the measurement of the FMF angle obtained at a precise mid-sagittal acquisition at 0° from the one after reconstruction was calculated. Differences of 3° or less were regarded as acceptable².

RESULTS

The median gestation was 13 (11 + 0 to 13 + 6) weeks and the median fetal crown-rump length was 68 (45–84) mm. The median FMF angle obtained at a precise mid-sagittal acquisition with the direction of the nose being parallel to the face of the transducer was 79° ($74-85^\circ$).

In the reconstructed ideal profile view from the volumes acquired in the mid-sagittal plane, it was possible to demonstrate the landmarks that define the FMF angle in 90–100% of cases when the angle between the face of the transducer and the direction of the fetal nose at the time of volume acquisition was about $0-99^\circ$, $150-199^\circ$ and $330-359^\circ$ (Figure 3, Table 1). When the acquisition angle was $100-149^\circ$ or $200-329^\circ$, the presence of skull bones prevented adequate visualization of the profile in 80–90% of cases.

In a previous reproducibility study² we reported that in about 95% of cases the difference between two measurements of the FMF angle by the same observer or measurements by different observers is within 3° . In the current study we found that the difference in the measurement of the FMF angle obtained at a precise mid-sagittal acquisition at 0° from the one after reconstruction

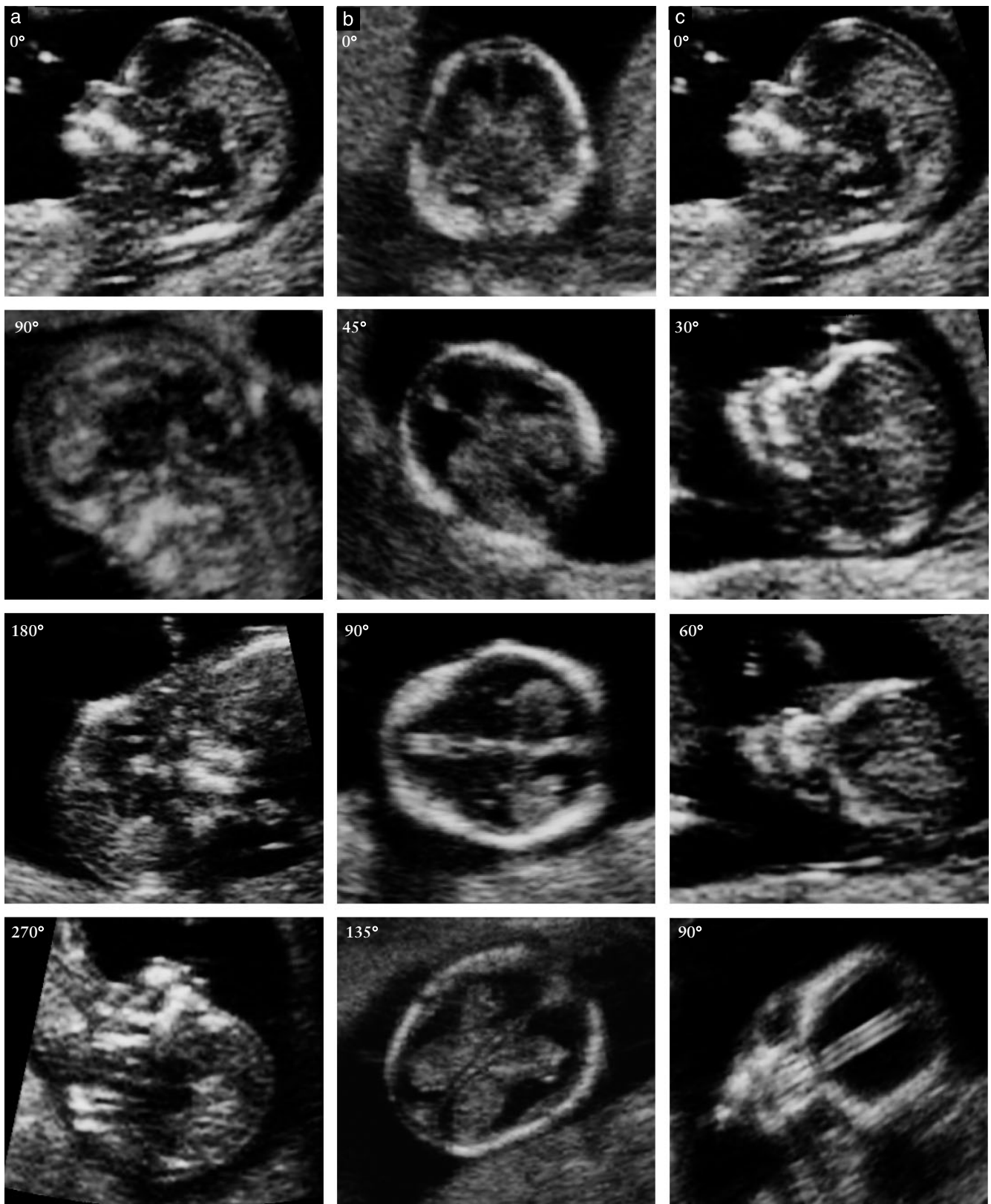


Figure 2 Planes of volume acquisition. (a) Mid-sagittal sections of the fetal profile with the angle between the face of the transducer and the direction of the fetal nose being 0°, 90°, 180° and 270°. (b) Transverse sections at the level of the biparietal diameter with the angle between the transducer and the midline echo of the brain being 0°, 45°, 90° and 135°. (c) Oblique sections around the crown–rump axis with the angle between the transducer and the mid-sagittal plane of the fetal profile being 0°, 30°, 60° and 90°.

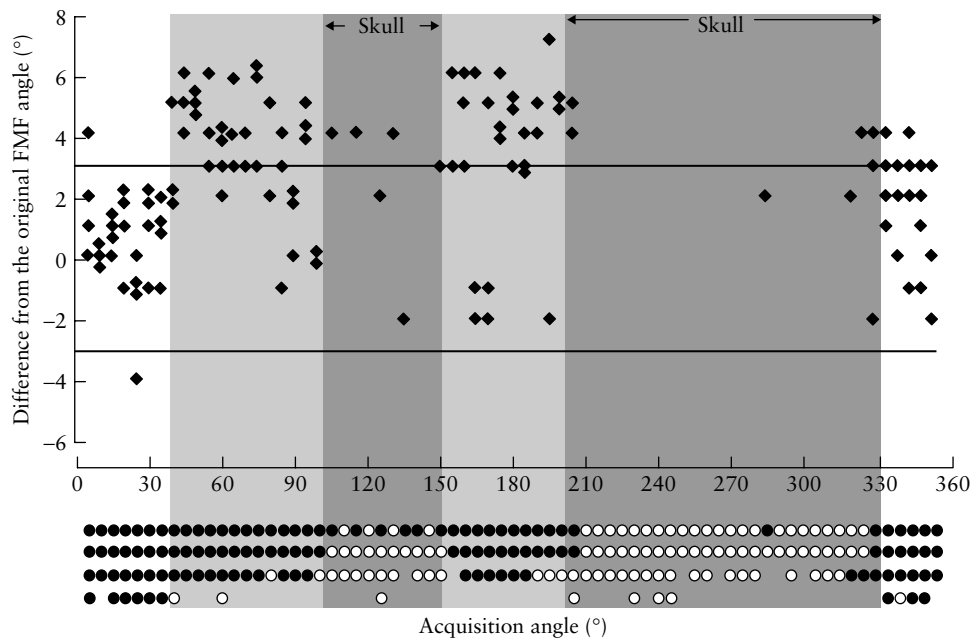


Figure 3 Ability to assess the frontomaxillary facial (FMF) angle (●, measurable; ○, not measurable) in the reconstructed mid-sagittal section, in cases where the plane of volume acquisition is mid-sagittal with a rotation of 0–359° from the direction of the nose (0°). The shaded area represents the angles of acquisition at which assessment of the FMF angle was not possible because of the skull bones (dark shade) or the measured angle was overestimated (light shade).

Table 1 Successful assessment of the frontomaxillary facial angle after appropriate sectioning of the three-dimensional volume of the head according to the initial plane and angle of acquisition

Acquisition plane	Total assessed (n)	Successfully assessed (n (%))	Angle difference > 3° (n (%))*
Mid-sagittal with rotation of 0–39° from the direction of the nose (0°)	27	27 (100)	1 (4)
Mid-sagittal with rotation of 40–99° from the direction of the nose (0°)	41	37 (90)	21 (57)
Mid-sagittal with rotation of 100–149° from the direction of the nose (0°)	30	6 (20)	—
Mid-sagittal with rotation of 150–199° from the direction of the nose (0°)	29	26 (90)	16 (62)
Mid-sagittal with rotation of 200–329° from the direction of the nose (0°)	77	8 (10)	—
Mid-sagittal with rotation of 330–359° from the direction of the nose (0°)	19	18 (95)	2 (11)
Transverse at the level of BPD with rotation of 0–29°	37	35 (95)	—
Transverse at the level of BPD with rotation of 30–179°	98	20 (20)	—
Oblique with rotation of 0–49° around the crown–rump axis from the profile (0°)	58	52 (90)	—
Oblique with rotation of 50–89° around the crown–rump axis from the profile (0°)	49	2 (4)	—

*Values shown for those in which visualization was achieved in ≥ 90% in the mid-sagittal plane. BPD, biparietal diameter.

was 3° or less when the angle of acquisition was 0–39° or 330–359° and more than 3° when the angle of acquisition was 40–99° and 150–199°.

In the reconstructed precise profile view, from the volumes acquired in the transverse plane at the level of the biparietal diameter, it was possible to demonstrate the landmarks that define the FMF angle in 95% of cases when the angle of acquisition was 0–29° (Figure 4, Table 1). Similarly, in the volumes acquired in the oblique plane, measurement of the FMF angle was possible in 90% of cases when the angle of acquisition was 0–49° (Figure 4, Table 1). When the acquisition angle in the transverse plane was 30° or more and in the oblique plane it was 50° or more, it was usually not possible (in 80% and 96% of cases, respectively) to measure

the FMF angle in the reconstructed precise profile view because the necessary landmarks had been obscured by the skull.

DISCUSSION

The data from this study demonstrate that a reliable measurement of the FMF angle is entirely dependent on the plane and angle of acquisition. Thus, in reconstructed images it was possible to visualize the necessary landmarks of the upper anterior corner of the maxilla, the upper palate and the bony forehead, and to obtain a reliable measurement of the FMF angle when the plane of acquisition was: (a) mid-sagittal with the angle between the face of the transducer and the direction of the fetal

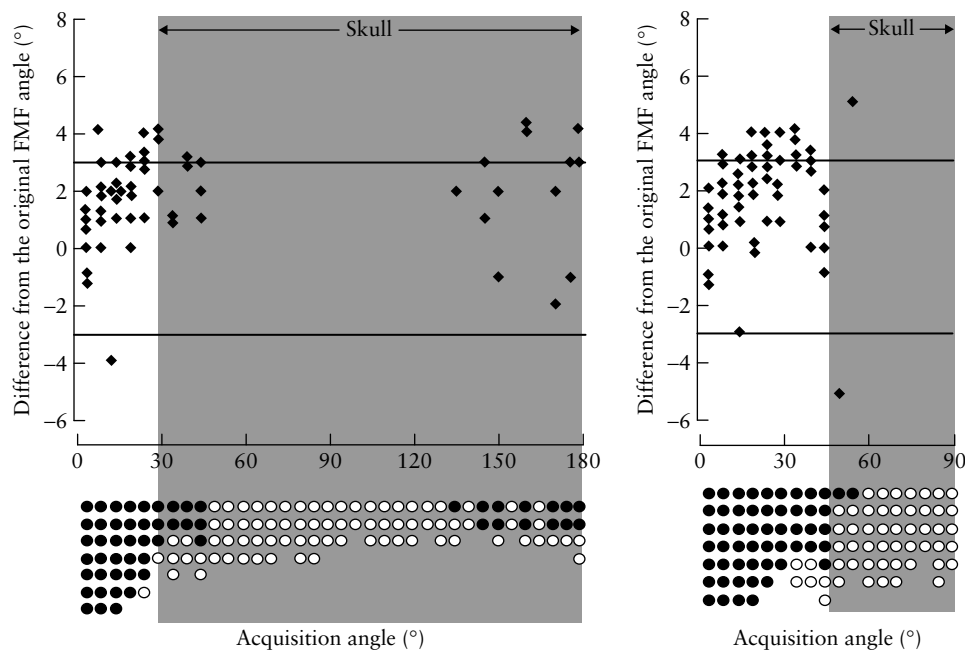


Figure 4 Ability to assess the frontomaxillary facial (FMF) angle (●, measurable; ○, not measurable) in the reconstructed mid-sagittal section in cases where the volume acquisition plane is: (a) transverse at the level of the biparietal diameter, with rotation of 0–180°; and (b) oblique with rotation of 0–90° around the crown–rump axis from the profile (0°). The shaded area represents the angles of acquisition at which assessment of the FMF angle was not possible because of the skull bones.

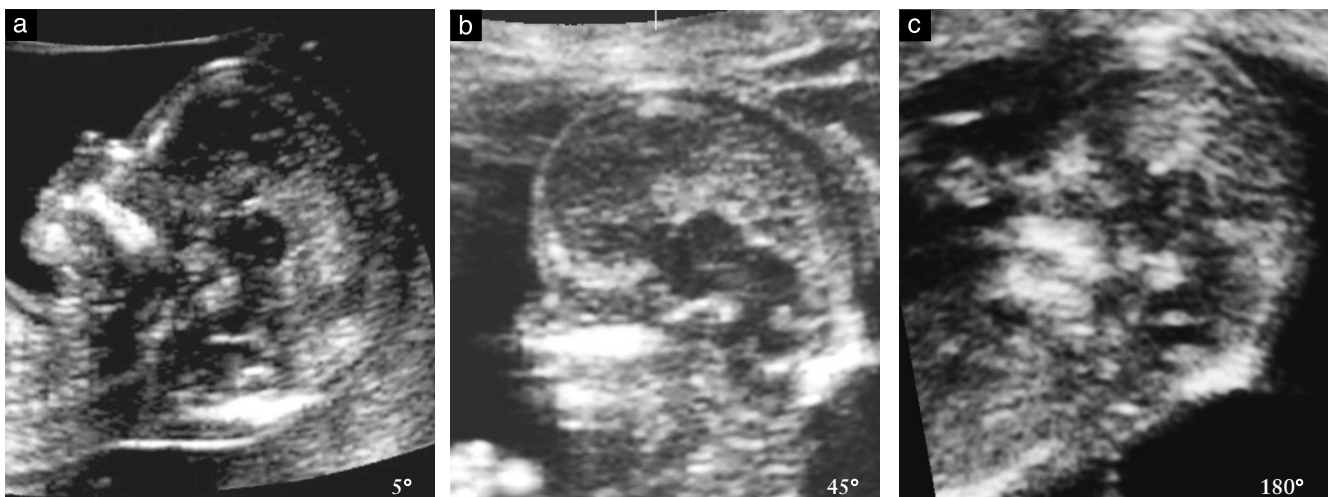


Figure 5 Mid-sagittal acquisition of the fetal head with the angle between the face of the transducer and the nose being 5° (a), 45° (b) and 180° (c). At 5° the maxillary palatal complex is rectangular and the anterior margin is clearly visible. At 45° it is not possible to delineate the anterior margin of the maxilla and in the forehead the bone cannot be distinguished from the overlying skin. At 180° the anterior margin of the maxilla is not possible to define and at the forehead neither the skin nor the bone are visible.

nose being 0–39° or 330–359°; (b) transverse, with the angle between the transducer and the midline echo of the brain being 0–29°; and (c) oblique, starting from the mid-sagittal plane of the fetal profile and rotating around the crown–rump axis to the coronal plane from 0° to 49°.

The presence of skull bones prevents adequate visualization of the profile when the acquisition angle in the mid-sagittal plane is 100–149° or 200–329°; in the transverse plane it is > 30°; and in the oblique plane it is > 50°. Consequently, in the reconstructed images from such volumes it is not possible to see the necessary landmarks for measurement of the FMF angle.

Another important finding of this study is that volume acquisition in certain fetal positions may produce a FMF angle which is substantially different from the one obtained in the precise mid-sagittal plane. Thus, when the angle of acquisition in the mid-sagittal plane was about 40–99° or 150–199°, most of the measured angles were > 3° higher than the FMF angle, measured in the precise mid-sagittal view. A likely explanation for this overestimate is that the bone and overlying skin in the forehead become indistinguishable, presumably because at these angles of acquisition the ultrasound beam becomes parallel to these structures (Figure 5).

In conclusion, with 3D ultrasound there is an erroneous concept that, irrespective of the position of the head, a volume could be obtained and, after appropriate manipulation, any desired structure could be identified. The data from the present study demonstrate that, with 3D ultrasound, the extent to which a given structure, in this case the maxillary, palatal and frontal bones, can be demonstrated in their actual shape and with well-defined contours is entirely dependent on the plane and angle of the volume acquisition.

ACKNOWLEDGMENT

This study was supported by a grant from The Fetal Medicine Foundation (Charity No. 1037116).

REFERENCES

1. Sonek JD, Borenstein M, Dagklis T, Persico N, Nicolaides KH. Frontomaxillary facial angle in fetuses with trisomy 21 at 11–13(6) weeks. *Am J Obstet Gynecol* 2007; **196**: 271.e1–4.
2. Plasencia W, Dagklis T, Sotiriadis A, Borenstein M, Nicolaides KH. Frontomaxillary facial angle at 11+0 to 13+6 weeks' gestation – reproducibility of measurements. *Ultrasound Obstet Gynecol* 2007; **29**: 18–21.
3. Rembouskos G, Cicero S, Longo D, Vandecruys H, Nicolaides KH. Assessment of the fetal nasal bone at 11–14 weeks of gestation by three-dimensional ultrasound. *Ultrasound Obstet Gynecol* 2004; **23**: 232–236.
4. Plasencia W, Dagklis T, Borenstein M, Csapo B, Nicolaides KH. Assessment of the corpus callosum at 20–24 weeks of gestation by three-dimensional ultrasound. *Ultrasound Obstet Gynecol* 2007. DOI: 10.1002/uog.4035.