

Placental volume measured by three-dimensional ultrasound at 11 to 13 + 6 weeks of gestation: relation to chromosomal defects

P. WEGRZYN, C. FARO, O. FALCON, C. F. A. PERALTA and K. H. NICOLAIDES

Harris Birthright Research Centre for Fetal Medicine, King's College Hospital Medical School, London, UK

KEYWORDS: chromosomal defects; first trimester; placental volume; screening; three-dimensional ultrasound; VOCAL

ABSTRACT

Objective To determine the potential value of measuring the placental volume at 11 to 13 + 6 weeks of gestation in screening for chromosomal defects.

Methods The placental volume was measured using three-dimensional ultrasound in 500 consecutive singleton pregnancies immediately before chorionic villus sampling for fetal karyotyping at 11 to 13 + 6 (median, 12) weeks of gestation.

Results The fetal karyotype was normal in 417 pregnancies and abnormal in 83. In the chromosomally normal group the mean placental volume increased significantly with gestation from a mean of 51 mL (5th and 95th centiles: 31.2 and 82.4 mL) at 11 weeks to 91 mL (5th and 95th centiles: 55.7 and 147.2 mL) at 13 + 6 weeks. In the chromosomally abnormal group the mean placental volume for gestational age was not significantly different from normal in trisomy 21 and Turner syndrome, but it was smaller in trisomies 13 and 18.

Conclusions The measurement of the placental volume at 11 to 13 + 6 weeks of gestation is unlikely to be a useful predictor of the major chromosomal defects. In trisomies 13 and 18 the small placental volume may be due to early-onset fetal growth restriction, which could be the consequence of impaired placental function. Copyright © 2005 ISUOG. Published by John Wiley & Sons, Ltd.

INTRODUCTION

In this study we investigated the potential value of the placental volume, measured by three-dimensional (3D) ultrasound at 11 to 13 + 6 weeks of gestation, in screening

for chromosomal defects. A previous study reported that in 17 chromosomally abnormal fetuses, including nine with trisomy 21, the placental volume corrected for fetal crown–rump length (CRL) was significantly decreased¹. Furthermore, the study suggested that measurement of placental volume may improve first-trimester screening for trisomy 21 by measurement of fetal nuchal translucency (NT)^{1–3}.

METHODS

The placental volume was measured using 3D ultrasound before fetal karyotyping by chorionic villus sampling at 11 to 13 + 6 weeks of gestation in 500 consecutive singleton pregnancies with known last menstrual period date and regular menstrual cycles of 26–30 days' duration. The study was carried out in our center during a 10-month period (December 2003 to September 2004). In all cases there was prior screening for chromosomal defects by a combination of maternal age and fetal NT, and the patients included in the study were those that opted for invasive testing after counseling³. All scans were carried out by sonographers with extensive experience in 3D ultrasound.

A 3D volume of the uterus was acquired by transabdominal sonography (RAB 4-8L probe, Voluson 730 Expert, GE Medical Systems, Milwaukee, WI, USA). The sweep angle was set at 85° and it was aimed so that the probe was perpendicular to the placental plate. The VOCAL (Virtual Organ Computer-aided AnaLysis) technique was then used to obtain a sequence of 12 sections of the placenta, each after a 15° rotation from the previous one. In each of the 12 planes the contour of the placenta was drawn manually, taking care to exclude the uterine wall, which at this gestation is usually

Correspondence to: Prof. K. H. Nicolaides, Harris Birthright Research Centre for Fetal Medicine, King's College Hospital Medical School, Denmark Hill, London SE5 9RS, UK (e-mail: fmf@fetalmedicine.com)

Accepted: 25 January 2005

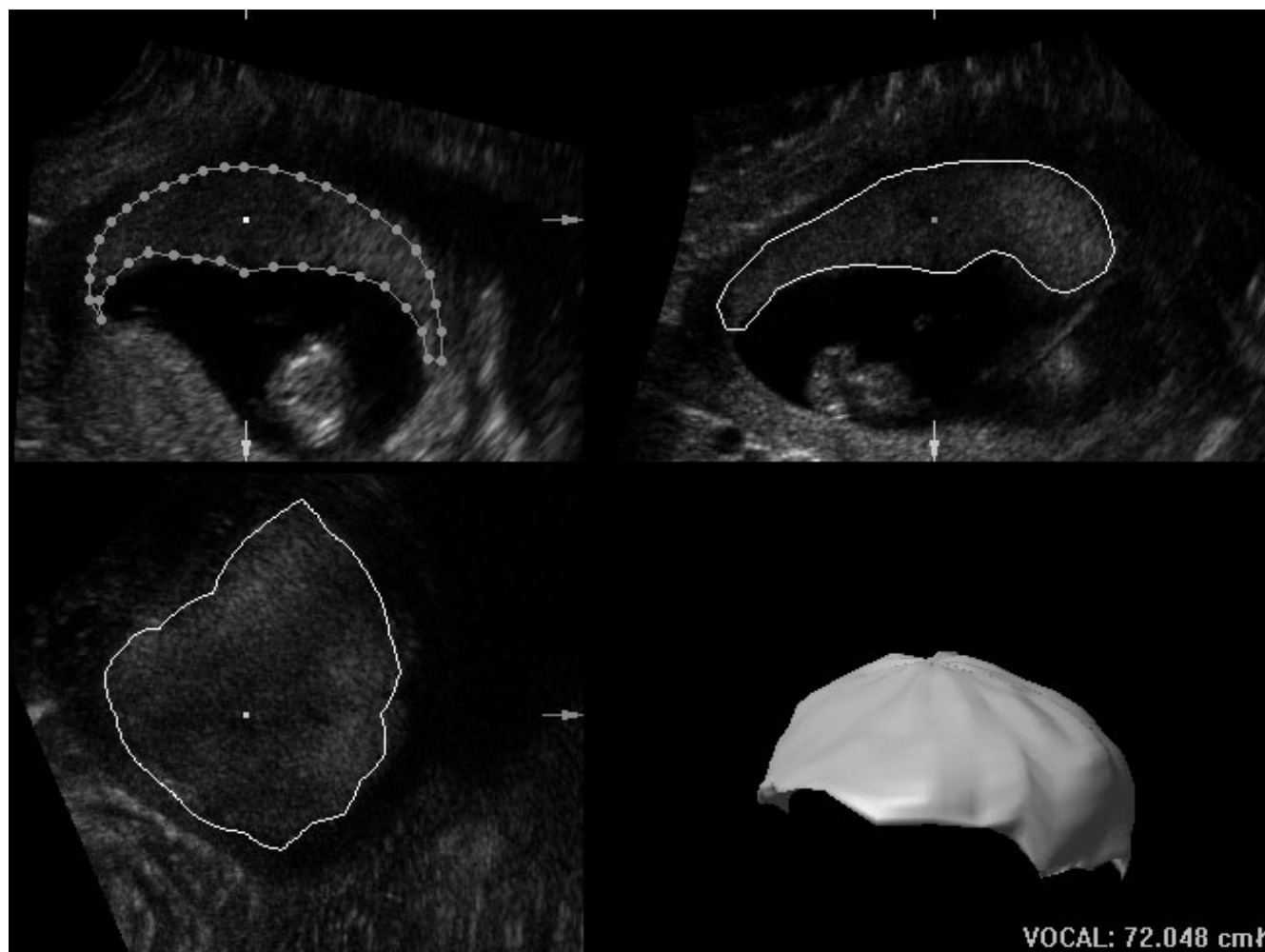


Figure 1 Three-dimensional volume of the placenta obtained using the Virtual Organ Computer-aided AnaLysis (VOCAL) technique.

thickened under the placenta, either due to hypertrophy or contraction (Voluson 730 Expert Operation Manual, GE Medical Systems). The machine calculates a volume from the areas highlighted in each of the 12 planes and when the calculation is finished the computed reconstruction of the organ is displayed together with the volume (Figure 1). Every measurement was done offline after the scan by the same operator and before knowing the result of the karyotype.

In 40 randomly selected cases the placental volume was measured by the same sonographer twice and also by a second sonographer once in order to compare the measurements and calculate intra- and interobserver agreement.

Statistical analysis

In the chromosomally normal group, linear regression was used to determine the significance of the association between placental volume and gestational age in days. The Shapiro–Wilks' W -test demonstrated that the data were not normally distributed and therefore they were log transformed to achieve a normal distribution. Each measurement of the log-transformed placental volume

was then expressed as a deviation from the expected mean for gestation (delta value) and unpaired t -test was used to determine the significance of differences in the delta values between the chromosomally normal and abnormal groups. The same analysis was performed to determine the association between placental volume and CRL.

The Bland–Altman analysis was used to compare the measurement agreement and bias for a single examiner and between different examiners⁴. In all the analyses a value for $P < 0.05$ was considered to be significant. The analyses were performed using Statistica for Windows 1999 (StatSoft, Inc., Tulsa, OK, USA) and Excel for Windows 2000 (Microsoft Corp., Redmond, WA, USA).

RESULTS

The median maternal age was 37 (range, 19–47) years, the median fetal CRL was 67 (range, 45–84) mm and the median gestation was 12 (range, 11 to 13 + 6) weeks. The placental volume was successfully measured in all cases. The fetal karyotype was normal in 417 pregnancies and abnormal in 83 (Tables 1 and 2). In the chromosomally normal group the placental volume increased significantly with gestation from a mean

of 51 mL (5th and 95th centiles: 31.2 and 82.4 mL) at 11 weeks to 91 mL (5th and 95th centiles: 55.7 and 147.2 mL) at 13 + 6 weeks (Ln placental volume = $0.029 \times \text{gestation in days} + 1.693$, Ln SD = 0.319, $r = 0.373$, $P < 0.0001$; Figure 2) and with CRL from a mean of 47 mL (5th and 95th centiles: 27.7 and 73.9 mL) at a CRL of 45 mm to 102 mL (5th and 95th centiles: 64.8 and 161.3 mL) at a CRL of 84 mm (Ln placental volume = $0.020 \times \text{CRL} + 2.947$, Ln SD = 0.319, $r = 0.496$, $P < 0.0001$; Figure 3). The CRL increased with gestation, from a mean of 48 mm at 11 weeks to 79 mm at 13 + 6 weeks (CRL = $1.480 \times \text{gestation in days} - 65.876$, $r = 0.766$, $P < 0.001$).

In trisomies 13 and 18 the mean placental volume both for gestation and CRL was significantly smaller than

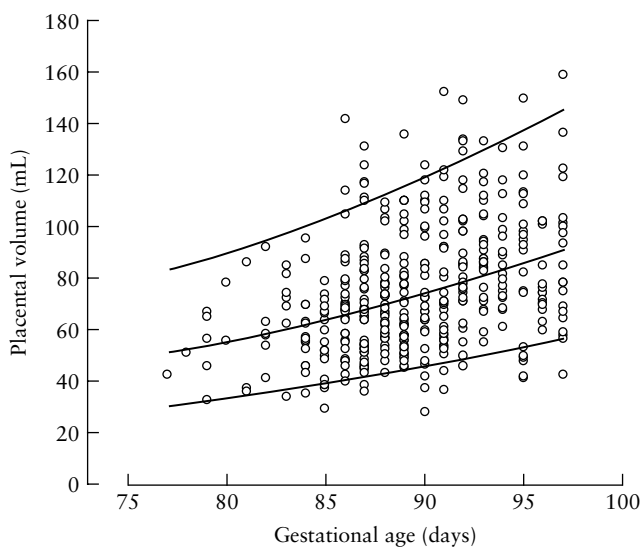


Figure 2 Reference range (mean, 95th and 5th centiles) of placental volume with gestation in the chromosomally normal pregnancies at 11 to 13 + 6 weeks of gestation.

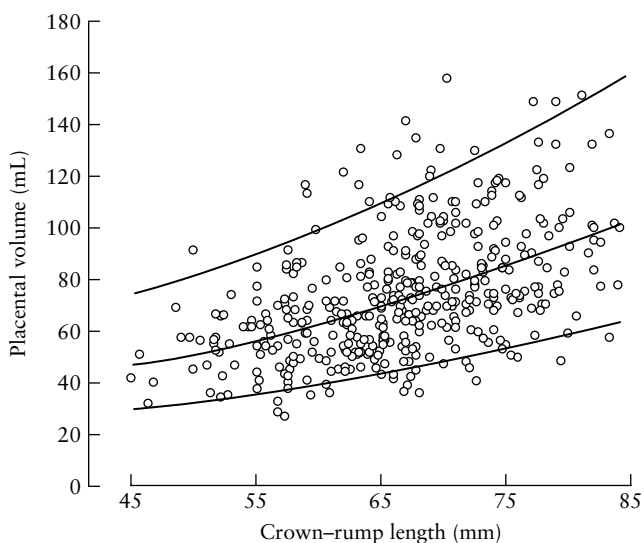


Figure 3 Reference range (mean, 95th and 5th centiles) of placental volume with crown-rump length in the chromosomally normal pregnancies at 11 to 13 + 6 weeks of gestation.

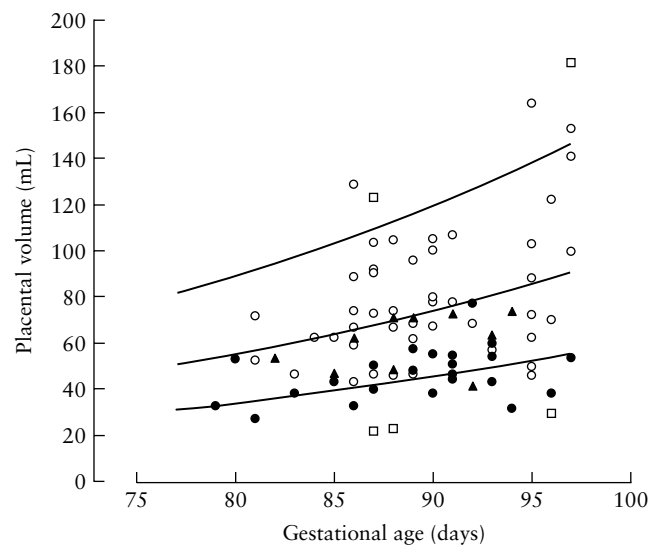


Figure 4 Placental volume in chromosomal defects plotted on the reference range (mean, 95th and 5th centiles) with gestation of the chromosomally normal pregnancies. Trisomy 21 (○), trisomies 13 and 18 (●), Turner syndrome (▲), triploidy (□).

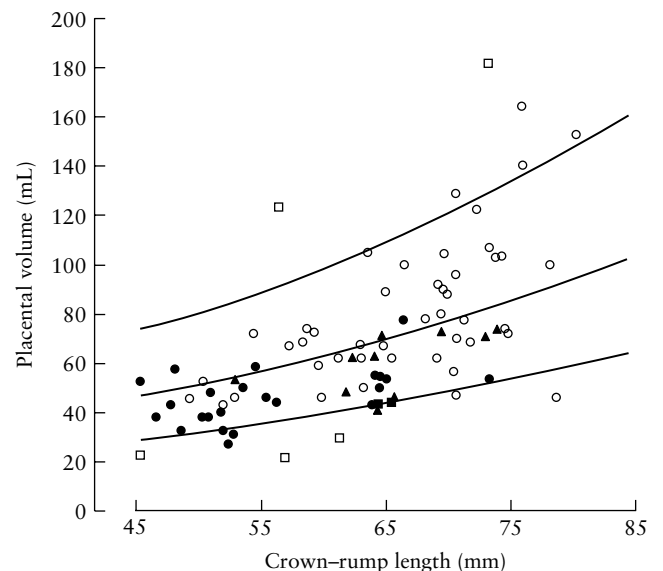


Figure 5 Placental volume in chromosomal defects plotted on the reference range (mean, 95th and 5th centiles) with crown-rump length of the chromosomally normal pregnancies. Trisomy 21 (○), trisomies 13 and 18 (●), Turner syndrome (▲), triploidy (□).

normal, but in trisomy 21 and Turner syndrome it was not significantly different from normal (Tables 1 and 2, Figures 4 and 5). At 12 weeks the mean placental volume in chromosomally normal fetuses was 62 mL and in those with trisomy 13 or 18 it was 40 mL. In the five cases of triploidy there were three with a small and two with a large placenta (Figures 4 and 5).

In the Bland-Altman plot the mean difference between paired measurements by the same sonographer was 0.6 mL and the 95% limits of agreement were -6.1 mL (95% CI, -8.0 to -4.3 mL) to 7.4 mL (95% CI, 5.5-9.2 mL). The mean difference between paired measurements by two sonographers was 0.7 mL and the

Table 1 Mean differences in placental volume from the normal mean for gestation in the chromosomally normal and abnormal pregnancies

Karyotype	n	Ln mean difference in placental volume for GA (95% CI for ln mean)	P (unpaired t-test)
Normal	417	-0.024 (-0.053 to 0.004)	
Trisomy 21	45	0.035 (-0.059 to 0.130)	0.2034
Trisomy 18	17	-0.469 (-0.600 to -0.339)	<0.0001
Turner syndrome	10	-0.197 (-0.343 to -0.051)	0.6661
Trisomy 13	6	-0.467 (-0.638 to -0.297)	0.0027

There were five cases of triploidy, three with a small and two with a large placenta (Figures 4 and 5). GA, gestational age.

Table 2 Mean differences in placental volume from the normal mean for crown-rump length in the chromosomally normal and abnormal pregnancies

Karyotype	n	Ln mean difference in placental volume for CRL (95% CI for ln mean)	P (unpaired t-test)
Normal	417	-0.016 (-0.043 to -0.011)	
Trisomy 21	45	0.057 (-0.026 to 0.139)	0.09459
Trisomy 18	17	-0.214 (-0.327 to -0.100)	0.00386
Turner syndrome	10	-0.174 (-0.305 to -0.043)	0.07343
Trisomy 13	6	-0.33925 (-0.527 to -0.152)	0.00460

There were five cases of triploidy, three with a small and two with a large placenta (Figures 4 and 5). CRL, crown-rump length.

95% limits of agreement were -10.5 mL (95% CI, -13.1 to -7.8 mL) to 9.2 mL (95% CI, 6.5-11.8 mL).

DISCUSSION

This study has demonstrated first that 3D ultrasound can provide a reproducible measurement of the placental volume, second that in normal pregnancy placental volume increases with gestation and third that trisomies 13 and 18 are associated with a small placenta.

In normal pregnancy there is a doubling in placental volume between 11 and 13 + 6 gestational weeks, which is accompanied by a simultaneous doubling in fetal size and gestational sac volume⁵. In previous studies investigating placental volume in early pregnancy by 3D ultrasound a series of parallel sections of approximately 1 cm in thickness were used^{1,6,7}. In the present study placental volume was estimated using 12 sections obtained by the rotational VOCAL technique. There is some evidence from *in-vitro* studies that in the estimation of volumes of an irregular object, such as the placenta, the VOCAL technique may be more accurate^{8,9}.

In trisomies 13 and 18 the mean placental volume was significantly smaller than normal and it was below the 5th centile of the normal range in 39% of cases. This is consistent with the finding that in these chromosomal defects at 11 to 13 + 6 weeks the maternal

serum concentration of both free beta-human chorionic gonadotropin (β -hCG) and pregnancy-associated plasma protein-A (PAPP-A) is on average about one-third of the normal concentration^{10,11}. In terms of first-trimester screening for trisomies 13 and 18 it is unlikely that the detection rate will be improved by the measurement of placental volume. First, the detection rate of these trisomies by a program combining maternal age with fetal NT and maternal serum free β -hCG and PAPP-A is more than 90%. Second, there is a significant association between placental volume and maternal serum free β -hCG and PAPP-A and therefore measurement of placental volume may have little to add to maternal serum testing¹². Third, these trisomies are often associated with other easily detectable first-trimester sonographic markers such as exomphalos and small CRL in trisomy 18 and megacystis, holoprosencephaly and tachycardia in trisomy 13^{10,11}.

In trisomy 21 pregnancies the placental volume, both for gestation and fetal CRL, is not significantly different from normal and it was below the 5th centile of the normal range in only two of our 45 cases. Consequently, measurement of placental volume is not useful in screening for trisomy 21. Similarly, in Turner syndrome placental volume was not significantly different from normal. The findings in triploidy, that in some cases the placental volume is substantially increased and in others it is substantially decreased, presumably reflect the two different origins of this chromosomal abnormality. Thus, in diandric triploidy, with a double paternal chromosomal constitution, there is a large molar placenta and a 10-fold increase in maternal serum free β -hCG, whereas digynic triploidy is associated with a very small placenta and a 10-fold reduction in the concentration of placental products in the maternal circulation¹³.

ACKNOWLEDGMENT

This study was supported by a grant from The Fetal Medicine Foundation (Charity No. 1 037 116).

REFERENCES

- Metzenbauer M, Hafner E, Schuchter K, Philipp K. First-trimester placental volume as a marker for chromosomal anomalies: preliminary results from an unselected population. *Ultrasound Obstet Gynecol* 2002; **19**: 240-242.
- Nicolaides KH. Nuchal translucency and other first-trimester sonographic markers of chromosomal abnormalities. *Am J Obstet Gynecol* 2004; **191**: 45-67.
- Snijders RJ, Noble P, Sebire N, Souka A, Nicolaides KH. UK multicentre project on assessment of risk of trisomy 21 by maternal age and fetal nuchal translucency thickness at 10-14 weeks of gestation. Fetal Medicine Foundation First Trimester Screening Group. *Lancet* 1998; **352**: 343-346.
- Bland JM, Altman DG. Applying the right statistics: analyses of measurement studies. *Ultrasound Obstet Gynecol* 2003; **22**: 85-93.
- Falcon O, Wegrzyn P, Faro C, Peralta CFA, Nicolaides KH. Gestational sac volume measured by three-dimensional ultrasound at 11 to 13 + 6 weeks of gestation: relation to

- chromosomal defects. *Ultrasound Obstet Gynecol* 2005; **25**: 546–550.
6. Hafner E, Philipp T, Schuchter K, Dillinger-Paller B, Philipp K, Bauer P. Second-trimester measurements of placental volume by three-dimensional ultrasound to predict small-for-gestational-age infants. *Ultrasound Obstet Gynecol* 1998; **12**: 97–102.
 7. Hafner E, Schuchter K, van Leeuwen M, Metzenbauer M, Dillinger-Paller B, Philipp K. Three-dimensional sonographic volumetry of the placenta and the fetus between weeks 15 and 17 of gestation. *Ultrasound Obstet Gynecol* 2001; **18**: 116–120.
 8. Raine-Fenning N, Campbell B, Collier J, Brincat M, Johnson I. The reproducibility of endometrial volume acquisition and measurement with the VOCAL-imaging program. *Ultrasound Obstet Gynecol* 2002; **19**: 69–75.
 9. Raine-Fenning NJ, Clewes JS, Kendall NR, Bunkheila AK, Campbell BK, Johnson IR. The interobserver reliability and validity of volume calculation from three-dimensional ultrasound datasets in the *in-vitro* setting. *Ultrasound Obstet Gynecol* 2003; **21**: 283–291.
 10. Sniijders RJ, Sebire NJ, Nayar R, Souka A, Nicolaides KH. Increased nuchal translucency in trisomy 13 fetuses at 10–14 weeks of gestation. *Am J Med Genet* 1999; **86**: 205–207.
 11. Sherod C, Sebire NJ, Soares W, Sniijders RJM, Nicolaides KH. Prenatal diagnosis of trisomy 18 at the 10–14-week ultrasound scan. *Ultrasound Obstet Gynecol* 1997; **10**: 387–390.
 12. Metzenbauer M, Hafner E, Hoefinger D, Schuchter K, Stangi G, Ogrris E, Philipp K. Three-dimensional ultrasound measurement of the placental volume in early pregnancy: method and correlation with biochemical placenta parameters. *Placenta* 2001; **22**: 602–605.
 13. Spencer K, Liao AW, Skentou H, Cicero S, Nicolaides KH. Screening for triploidy by fetal nuchal translucency and maternal serum free beta-hCG and PAPP-A at 10–14 weeks of gestation. *Prenat Diagn* 2000; **20**: 495–499.