Ultrasound Obstet Gynecol 2003; **22**: 135–137
Published online 11 July 2003 in Wiley InterScience (www.interscience.wiley.com). **DOI:** 10.1002/uog.176

Learning curve for sonographic examination of the fetal nasal bone at 11–14 weeks

S. CICERO, V. DEZEREGA, E. ANDRADE, M. SCHEIER and K. H. NICOLAIDES

Harris Birthright Research Centre for Fetal Medicine, King's College Hospital Medical School, London, UK

KEYWORDS: chromosomal defects; first trimester; nasal bone; nuchal translucency; screening; trisomy 21; ultrasound

ABSTRACT

Objective *To determine the number of ultrasound examinations necessary for training sonographers to examine accurately the fetal nasal bone at 11–14 weeks' gestation.*

Methods *Fifteen sonographers with experience in measuring nuchal translucency were asked to examine the nasal bone during the routine 11–14-week scan. The supervising doctor recorded if the sonographer succeeded in obtaining the correct image. Each sonographer performed a total of 140 examinations, and the data were analyzed in seven groups of 20 examinations. In a second study, two sonographers with extensive experience in examining the nasal bone examined independently 100 consecutive patients at a median fetal crown–rump length of 65 (45–84) mm and median gestational age of 12 (11–14) weeks and recorded whether the nasal bone was absent or present.*

Results *In the first group of 20 examinations, there was failure to obtain the correct image of the fetal profile in 1–5 (median, 4) cases. In the subsequent three groups, there was failure to obtain the correct image in 0–3 (median, 1) cases. In the fifth and sixth groups failure occurred in 0–2 (median, 0) cases and in the seventh group all sonographers obtained successful images of the fetal profile in all cases. One sonographer obtained successful images of all cases after the first 40 scans, four after the first 60 scans, six after the first 80 and two each after the first 100 and 120 scans. In the second study, there was agreement between the two sonographers that the nasal bone was absent in two and present in 98 of the 100 consecutive patients examined.*

Conclusion *The minimum number of scans required for an experienced sonographer to become competent in examining the fetal nasal bone is on average 80, with a range of 40–120. Copyright © 2003 ISUOG. Published by John Wiley & Sons, Ltd.*

INTRODUCTION

At 11–14 weeks of gestation the nasal bone is not visible on sonographic examination in about 70% of fetuses with trisomy 21 and in < 1% of chromosomally normal fetuses[1]. Furthermore, in trisomy 21 pregnancies there is no significant difference in fetal nuchal translucency thickness or maternal serum free β-human chorionic gonadotropin and pregnancy-associated plasma protein-A between those with and those without a visible nasal bone[1,2]. Therefore, these sonographic and biochemical markers can be combined to provide a more effective method of early screening for trisomy 21, with an estimated detection rate of about 97% for a false-positive rate of 5%, or a detection rate of 90% for a false-positive rate of 2%. However, as with measurement of nuchal translucency thickness, it is imperative that those performing a nasal bone scan are appropriately trained and competent in carrying out this investigation.

The aim of this study was to determine the number of scans necessary for training of sonographers to examine accurately the fetal nasal bone at 11–14 weeks of gestation.

PATIENTS AND METHODS

A total of 15 sonographers, who had received The Fetal Medicine Foundation's Certificate of Competence in the 11–14-Week Scan, were given practical training on the following criteria for examination of the fetal profile for assessment of the presence or absence of the nasal bone: (a) the magnification of the image should be such that with each movement of the calipers there is an increment

Correspondence to: Prof. K. H. Nicolaides, Harris Birthright Research Centre for Fetal Medicine, King's College Hospital Medical School, Denmark Hill, London SE5 8RX, UK (e-mail: fmf@fetalmedicine.com)

Accepted: 9 May 2003

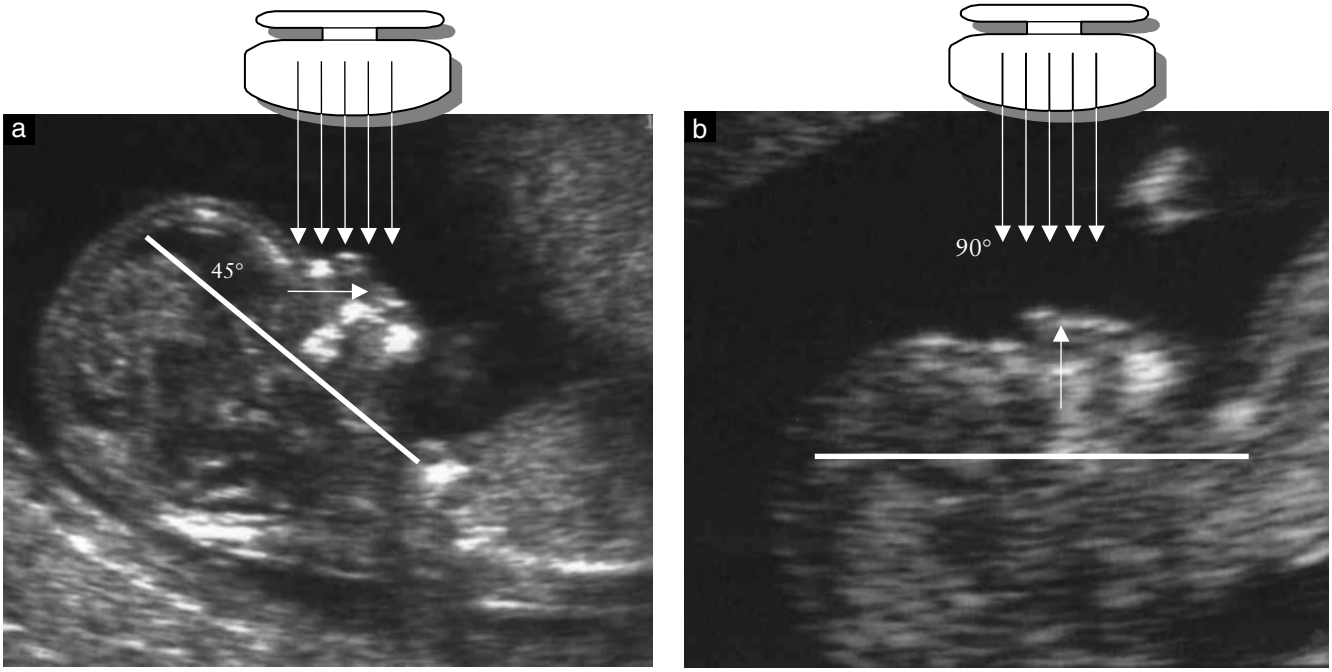

Figure 1 Ultrasound images demonstrating appropriate examination of fetal nasal bone: the angle between the ultrasound transducer and an imaginary line passing through the fetal profile should be about 45° (a) rather than 90° (b).

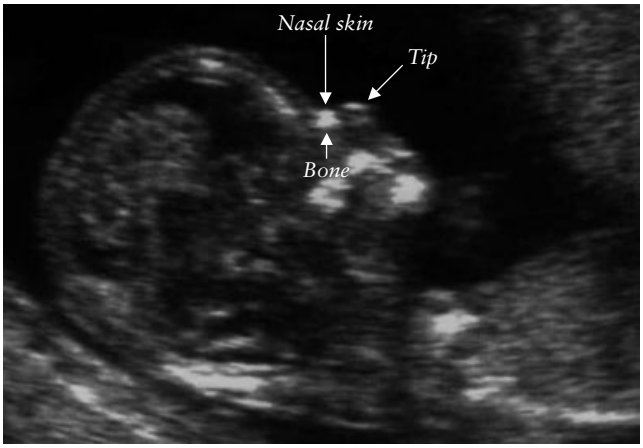

Figure 2 Ultrasound image showing the two parallel horizontal echogenic lines in the nose, the top one representing the skin and the bottom one representing the nasal bone and cartilage. A third line, almost continuous with the skin, but at a higher level, represents the tip of the nose.

Figure 3 Ultrasound image of fetal profile with the nasal cartilage line less echogenic than the skin line. This suggests the nasal bone is not calcified and it is therefore classified as being absent.

of only 0.1 mm; (b) a mid-sagittal view of the fetal profile should be obtained; (c) the angle between the ultrasound transducer and an imaginary line passing through the fetal profile should be about 45° (Figure 1). When these criteria are satisfied, it is possible to visualize at the level of the fetal nose three distinct lines. Two of them, proximal to the forehead, are horizontal and parallel to each other, resembling an 'equals sign'. The top line represents the skin and the bottom one, usually thicker and more echogenic than the overlying skin, represents the nasal bone. The third line, almost continuous with the skin, but at a higher level, represents the tip of the nose (Figure 2). When the nasal cartilage line appears as a thin line, less echogenic than the overlying skin, it suggests that the nasal bone is not yet calcified, and the bone is therefore classified as being absent (Figure 3).

The sonographers were asked to examine the nasal bone during the routine 11–14-week scan, under the direct supervision of a doctor who had received extensive training in examining the nasal bone. All scans were performed transabdominally, using a 5-MHz transducer and a Toshiba Powervision ultrasound machine (Toshiba, Tokyo, Japan). The supervising doctor recorded if the sonographer succeeded in obtaining the correct image. Each sonographer performed a total of 140 examinations, and the data were analyzed in seven groups of 20 examinations. For each group the number of failures in examining the fetal profile was recorded.

In a second study, two sonographers with extensive experience in examining the nasal bone examined

independently 100 consecutive patients at a median fetal crown–rump length of 65 (45–84) mm and median gestational age of 12 (11–14) weeks and recorded whether the nasal bone was absent or present.

RESULTS

In the first group of 20 examinations, there was failure to obtain the correct image of the fetal profile in 1–5 (median, 4) cases (Figure 4). In the subsequent three groups, there was failure to obtain the correct image in 0–3 (median, 1) cases. In the fifth and sixth groups failure occurred in 0–2 (median, 0) cases and in the seventh group all sonographers obtained successful images of the fetal profile in all cases.

Successful examination of the nasal bone was achieved in all cases by one sonographer after the first 40 scans, by four after the first 60 scans, by six after the first 80, by two after the first 100 and by two after the first 120 scans.

In the second study, there was agreement between the two sonographers that the nasal bone was absent in two and present in 98 of the 100 consecutive patients examined.

DISCUSSION

The findings of this study demonstrate that, for a sonographer who is experienced in measuring nuchal translucency thickness, the minimum number of scans required to become competent in examining the fetal nasal bone is on average 80 with a range of 40–120. Furthermore, there is concordance between experienced sonographers on the definition of presence or absence of the nasal bone. Similarly, a previous study on the measurement of nuchal translucency had established that the ability to obtain reproducible results improves with training and that good results are achieved after 80 scans[3].

The findings of our report[1] on the high association between absence of the nasal bone at 11–14 weeks and trisomy 21 were confirmed by the results of three subsequent studies. Otano *et al.*[4] reported absent nasal bone in 3/5 (60%) trisomy 21 fetuses and 1/175 (0.6%) chromosomally normal fetuses. Zoppi *et al.*[5] reported absent nasal bone in 19/27 (70%) trisomy 21 fetuses and 8/5485 (0.1%) chromosomally normal fetuses. Orlandi *et al.*[6] reported absent nasal bone in 10/15 (67%) trisomy 21 fetuses and 10/1000 (1%) chromosomally normal fetuses. In contrast, De Biasio and Venturini[7], examined retrospectively the images obtained for measurement of nuchal translucency from five fetuses with trisomy 21 and reported that the nasal bone was present in all cases. However, the five images that they published were inappropriate both for the measurement of nuchal translucency and for examination of the nasal bone, because they were either too small or the fetus was positioned too vertically or too obliquely.

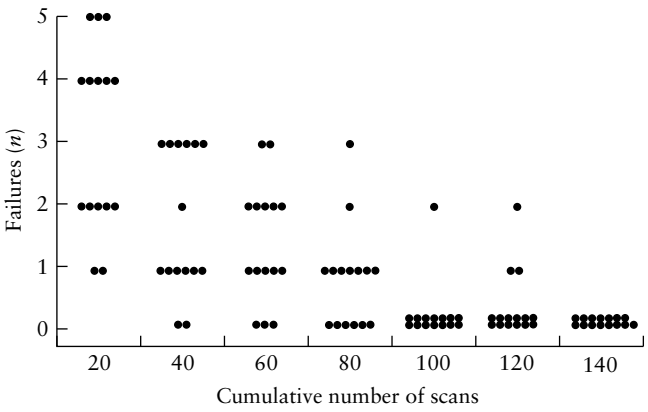

Figure 4 Number of failures to obtain the correct image for examination of the nasal bone in consecutive groups of 20 scans.

In screening for trisomy 21 at 11–14 weeks of gestation the finding of absence or presence of the fetal nasal bone has a major impact on the estimated risk for trisomy 21 and, therefore, on the patient's decision on for or against invasive testing[1]. Furthermore, examination of the nasal bone is more difficult than is measurement of nuchal translucency. Consequently, it is imperative that sonographers undertaking risk assessment by examination of the fetal profile receive appropriate training and certification of their competence in performing such a scan. As shown in this study, a good sonographer experienced in nuchal translucency scanning needs to perform on average 80 scans in order to achieve this level of competence.

ACKNOWLEDGMENT

This study was supported by a grant from The Fetal Medicine Foundation (Charity No: 1037116) and is part of the PhD Thesis of Dr S. Cicero, University of Tor Vergata, Rome, Italy.

REFERENCES

1. Cicero S, Curcio P, Papageorghiou A, Sonek J, Nicolaides KH. Absence of nasal bone in fetuses with trisomy 21 at 11–14 weeks of gestation: an observational study. *Lancet* 2001; **358**: 1665–1667.
2. Cicero S, Bindra R, Rembouskos G, Spencer K, Nicolaides KH. Integrated ultrasound and biochemical screening for trisomy 21 at 11 to 14 weeks. *Prenat Diagn* 2003; **23**: 306–310.
3. Braithwaite JM, Kadir RA, Pepera TA, Morris RW, Thompson PJ, Economides DL. Nuchal translucency measurement: training of potential examiners. *Ultrasound Obstet Gynecol* 1996; **8**: 192–195.
4. Otano L, Aiello H, Igarzabal L, Matayoshi T, Gadow EC. Association between first trimester absence of fetal nasal bone on ultrasound and Down's syndrome. *Prenat Diagn* 2002; **22**: 930–932.
5. Zoppi MA, Ibba RM, Axinan C, Floris M, Manca F, Monni G. Absence of fetal nasal bone and aneuploidies at first trimester nuchal translucency screening in 5425 unselected pregnancies. *Prenat Diagn* 2003; **23**: 496–500.
6. Orlandi F, Bilardo CM, Campogrande M, Krantz D, Hallahan T, Rossi C, Viora E. Measurement of nasal bone length at 11–14 weeks of pregnancy and its potential role in Down syndrome risk assessment. *Ultrasound Obstet Gynecol* 2003; **22**: 36–39.
7. De Biasio P, Venturini PL. Absence of nasal bone and detection of trisomy 21. *Lancet* 2002; **359**: 1344.

