*Ultrasound Obstet. Gynecol. 7 (1996) 245–250*

# Abnormalities of the heart and great arteries in chromosomally normal fetuses with increased nuchal translucency thickness at 11–13 weeks of gestation

*J. Hyett, G. Moscoso, G. Papapanagiotou, M. Perdu and K. H. Nicolaides*

Harris Birthright Centre for Fetal Medicine and Department of Early Human Development, King's College Hospital Medical School, London, UK

Key words: NUCHAL TRANSLUCENCY, CARDIAC DEFECTS, AORTIC ISTHMUS, PRENATAL DIAGNOSIS

## ABSTRACT

*Pathological examination of trisomic fetuses with increased nuchal translucency thickness at 11–13 weeks of gestation demonstrated a high prevalence of cardiac defects and abnormalities of the great arteries. This study reports the pathological findings observed from the examination of the heart and great arteries of 21 chromosomally normal fetuses with increased nuchal translucency. In 19 of the 21 cases there were abnormalities; the commonest was narrowing of the aorta at the level of the isthmus and immediately above the aortic valve. This finding is different from that in case of trisomy 21, where narrowing of the isthmus is associated with an increased diameter of the aortic valve. These findings suggest that abnormalities of the heart and great arteries may be implicated in the pathogenesis of increased nuchal translucency not only in trisomic fetuses but also in chromosomally normal fetuses. It can be implied that increased nuchal translucency thickness at 10–14 weeks of gestation may prove to be a useful marker for the identification of fetal cardiac abnormalities.*

## INTRODUCTION

Increased nuchal translucency thickness at 10–14 weeks of gestation is found in about 80% of trisomic fetuses[1,2]. A pathological study of 36 trisomy 21 fetuses with increased nuchal translucency has shown that 56% had atrioventricular or ventricular septal defects[3]. Similarly, a study of 19 fetuses with trisomy 18 found ventricular septal defects and/or polyvalvular abnormalities in all cases[4]. Additionally, examination of the great arteries demonstrated that in trisomy 21 there is narrowing of the aortic isthmus and dilatation immediately above the aortic valve, whereas the diameters of the pulmonary trunk and ductus arteriosus remain normal[5,6].

The aim of this study was to examine the possible association between increased nuchal translucency thickness and abnormalities of the heart and great arteries in chromosomally normal fetuses.

## PATIENTS AND METHODS

Pathological examination of the heart and great arteries was performed in 21 chromosomally normal fetuses after termination of pregnancy at 11–23 weeks of gestation. In 18 cases, chorionic villus sampling had been performed because of increased nuchal translucency thickness detected by ultrasound examination at 11–13 weeks. These patients were identified through an ongoing multicenter study of ultrasound screening for chromosomal defects at 10–14 weeks of gestation that has so far recruited more than 50 000 patients; increased nuchal translucency is defined by a measurement above the 95th centile of the normal range for crown–rump length[2]. Termination of pregnancy was carried out at the request of the parents, for the following reasons: in ten cases there was progressive fetal hydrops, in five cases there was a possible genetic syndrome, in two there was a large exomphalos and neural tube defects and in one there was bilateral renal agenesis. In three other cases, increased nuchal translucency was detected at the time of termination of pregnancy, which was carried out for psychosocial reasons. Cytogenetic analysis of fetal tissues demonstrated a normal karyotype.

In 15 pregnancies termination was by dilatation and evacuation and in six by induction of labor. At the time of

Correspondence: Professor K. H. Nicolaides, Harris Birthright Research Centre for Fetal Medicine, King's College Hospital Medical School, Denmark Hill, London SE5 8RX, UK



Received 5–9–95
Revised 30–11–95
Accepted 18–12–95

termination ultrasound examination demonstrated that in six cases there was spontaneous fetal death. The study was approved by our hospital Ethics Committee and tissue collection was made in accordance with the Polkinghorne guidelines on the research use of fetal material[7]. In each case the evacuated products of conception were examined systematically and the heart and great arteries were identified. The specimens were fixed by direct perfusion–inflation with 4% paraformaldehyde, and injected through the apex of each ventricle under microscopic control with the use of a low-pressure, high-flow perfusion technique[8]. Each specimen was fixed by simple immersion for a further 3 h and then rinsed and stored at 4 °C in sucrose phosphate buffer.

The heart was examined under a monocyclops dissecting microscope (Karl Zeiss, Oberkohen, Germany) with co-axial illumination. The atria were excised and the ventricles were divided into three segments – right paricta, septal and left parietal – by step-wise microdissection, allowing examination of the internal surface of both ventricles, the atrioventricular valves and the semilunar valves[8].

Prior to microdissection of the heart the external diameter of the great arteries was measured at eight points[5]. The aorta was measured immediately above the aortic valve and at the widest point of the ascending aorta. The aortic isthmus was measured immediately before the entry of the ductus arteriosus, and the descending, thoracic aorta was measured immediately below this point. The pulmonary trunk was measured immediately above the pulmonary valve, and at its widest point before the origin of the pulmonary arteries. The ductus arteriosus was measured proximal to the origin of the left pulmonary artery, and distally immediately before the point of entry into the thoracic aorta.

Each measurement of the great arteries was expressed as the number of standard deviations by which it differed from the appropriate normal mean for gestational age and expressed as a delta value[5]. A Mann–Whitney *U* test was used to determine the significance of the difference of the mean delta value from zero. Regression analysis was used to determine the significance of the association between delta values for each diameter and nuchal translucency thickness. Ratios of the aortic valve to the aortic isthmus and of the distal ductus arteriosus to the aortic isthmus were calculated and expressed as delta values. The significance of the difference between the mean delta value and zero was determined by the Mann–Whitney *U* test.

## RESULTS

Abnormalities of the heart and/or great arteries were found in 19 (90%) of the 21 cases (Table 1). Heart abnormalities

**Table 1** Cardiac defects and outcome of 21 chromosomally normal fetuses with increased nuchal translucency (NT) thickness

| *Case* | *GA* (weeks) | *NT* (mm) | *Outcome* | *Cardiac abnormality at postmortem* |
|---|---|---|---|---|
| 1 | 11 | 5 | progressed to hydrops; TOP at 13 weeks | bicuspid aortic valve; great vessels not available |
| 2 | 12 | 5 | progressed to hydrops; TOP at 17 weeks | normal heart; narrow aortic isthmus |
| 3 | 12 | 6 | progressed to hydrops; TOP at 15 weeks | normal heart; double aortic arch; narrow left aortic isthmus (c) |
| 4 | 11 | 6 | progressed to hydrops; IUD at 16 weeks | normal heart; narrow aortic isthmus |
| 5 | 12 | 7 | progressed to hydrops; IUD at 13 weeks | imperforate aortic valve; narrow ascending aorta and aortic isthmus; dilated pulmonary trunk and ductus arteriosus, (c) |
| 6 | 11 | 8 | progressed to hydrops; IUD at 16 weeks | normal heart; narrow aortic isthmus |
| 7 | 13 | 9 | progressed to hydrops; TOP at 20 weeks | normal heart; normal great vessels |
| 8 | 11 | 11 | progressed to hydrops; IUD at 15 weeks | normal heart; narrow aortic isthmus and ductus arteriosus |
| 9 | 13 | 12 | progressed to hydrops; TOP at 16 weeks | atrioventricular septal defect; narrow ascending aorta and aortic isthmus; dilated pulmonary trunk and ductus arteriosus (c) |
| 10 | 13 | 14 | progressed to hydrops; TOP at 15 weeks | dysplastic tricuspid valve, ventricular septal defect; narrow ascending aorta; interrupted aortic arch; dilated pulmonary trunk and ductus arteriosus (c) |
| 11 | 11 | 4 | TOP at 12 weeks | normal heart; narrow ascending aorta and aortic isthmus |
| 12 | 12 | 5 | TOP at 12 weeks | hypoplastic left heart; narrow ascending aorta and aortic isthmus (c) |
| 13 | 13 | 6 | TOP at 13 weeks | normal heart; narrow ascending aorta and aortic isthmus |
| 14 | 11 | 3 | renal agenesis; hydrops; TOP at 19 weeks | normal heart; narrow ductus arteriosus |
| 15 | 12 | 3 | exomphalos and spina bifida; IUD at 15 weeks | normal heart; normal great vessels |
| 16 | 12 | 6 | exomphalos and caudal regression; IUD at 13 weeks | ventricular septal defect; narrow aortic isthmus and distal ductus (c) |
| 17 | 11 | 3 | genetic syndrome; TOP at 19 weeks | normal heart; narrow ascending aorta; normal isthmus |
| 18 | 11 | 3 | absent radius and thumb with radial deviation of the hands; TOP at 12 weeks | ventricular septal defect; bicuspid aortic valve; narrow aortic isthmus (c) |
| 19 | 13 | 5 | multiple pterygium syndrome; TOP at 13 weeks | dysplastic tricuspid valve; narrow distal ductus arteriosus (c) |
| 20 | 12 | 5 | suspected Jarco–Lavine syndrome; TOP at 14 weeks | normal heart; narrow ductus arteriosus |
| 21 | 11 | 5 | Smith–Lemli–Opitz syndrome; TOP at 23 weeks | hypoplastic right ventricle; narrow ductus arteriosus (c) |

GA, gestational age; TOP, termination of pregnancy; IUD intrauterine death; (c), critical defects

were present in nine (43%) of the cases and these included septal defects (Figure 1) in four cases, valvular defects (Figure 2) in five, and one case each of hypoplastic left and hypoplastic right ventricle. Abnormalities of the great arteries were present in 18 (86%) of the cases. The commonest were those affecting the aortic arch; in 11 cases there was narrowing of the aortic isthmus, in one there was interruption of the aortic arch and in another there was a double aortic arch with a hypoplastic left aortic isthmus (Figure 3).

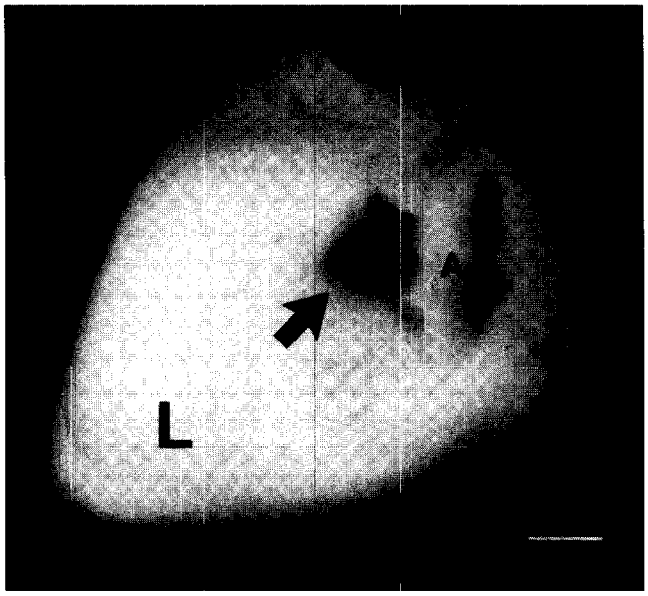


**Figure 1** Photomicrograph showing the left lateral view (L) of a large perimembranous ventricular septal defect (arrow) partially guarded by the septal leaflet of the tricuspid valve in a fetal heart at 12 weeks of gestation. A, left atrium; scale bar, 1 mm

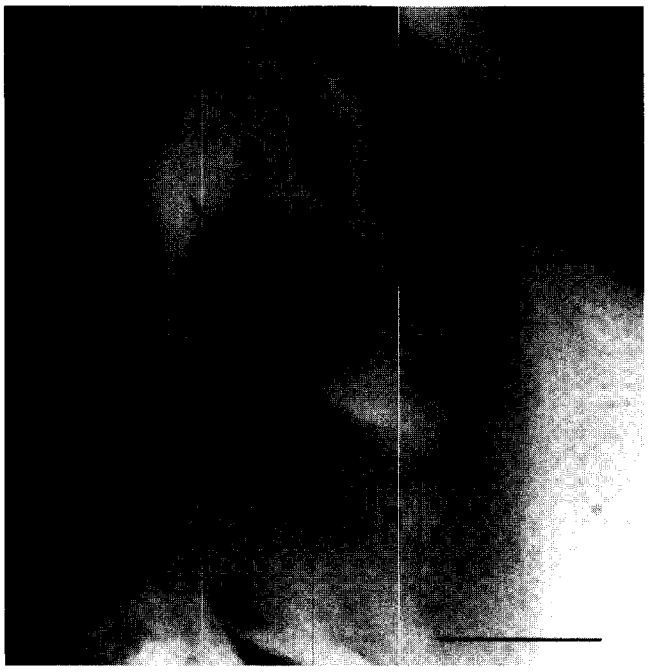

**Figure 2** Photomicrograph showing a bicuspid aortic valve (Av) in a fetal heart at 11 weeks of gestation. Note the two commisures (arrows) at 10 and 4 o'clock. Pv, pulmonary valve; R, right ventricle; scale bar, 1 mm

The external diameters of the great arteries were measured in 15 of the 21 cases. In the first three cases of the study no measurements were made and in another case the great arteries could not be identified. In two cases the anatomy of the great arteries was abnormal, and comparative measurements were not possible; the first was a case of interrupted aortic arch and the second had a double aortic arch with a hypoplastic left aortic isthmus. In the 15 cases with measurements, the mean aortic valve, the widest point of the ascending aorta and the aortic isthmus were decreased, but all other measurements were not significantly different from normal (Table 2, Figure 4). There was a significant association between delta nuchal translucency and both delta aortic valve ($r = -0.523$, $p < 0.05$; Figure 5) and delta aortic isthmus ($r = -0.674$, $p < 0.01$; Figure 5). The delta value of the ratio of the ductus arteriosus (measured distally to the origin of the left pulmonary artery) to the aortic isthmus was significantly higher than normal (mean 4.69, $Z = 3.61$, $p < 0.001$; Figure 4) as was the delta value of the ratio of the aortic valve to the aortic isthmus (mean 2.72, $Z = 4.38$, $p < 0.001$).

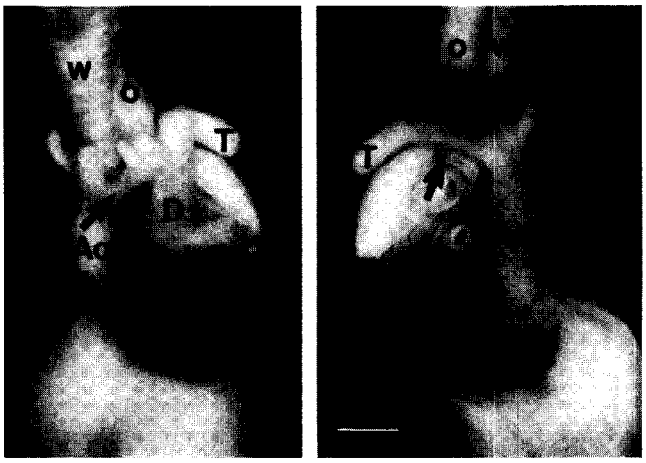


**Figure 3** Photomicrograph of the heart and great vessels in a 12-week fetus (case 3, Table 1), demonstrating a double aortic arch. On the left, the aortic isthmus (arrow) is hypoplastic, whereas on the right, the persisting right aortic arch (arrow) is dilated. Ao, ascending aorta; T, thoracic aorta; P, pulmonary trunk; D, ductus arteriosus; o, esophagus; w, trachea; scale bar, 1 mm

**Table 2** Mean delta values, compared to normal specimens, for vessel diameters in chromosomally normal fetuses with increased nuchal translucency thickness

| *Vessel segment* | *Mean* | *SE* | *Z* |
|---|---|---|---|
| Aortic valve | −1.175 | 0.322 | 3.17* |
| Ascending aorta | −1.618 | 0.382 | 3.78** |
| Aortic isthmus | −2.168 | 0.347 | 4.74** |
| Thoracic aorta | −0.673 | 0.410 | 1.96 |
| Pulmonary valve | −0.264 | 0.359 | 0.7235 |
| Pulmonary trunk | −0.465 | 0.416 | 1.13 |
| Proximal ductus arteriosus | −0.522 | 0.433 | 1.38 |
| Distal ductus arteriosus | −0.636 | 0.586 | 0.80 |

*$p < 0.01$;**$p < 0.001$

In the first 13 cases (Table 1), the only abnormality detected on ultrasound examination was increased nuchal translucency thickness. In case 14, bilateral renal agenesis was diagnosed at 19 weeks, and at postmortem examination in addition to the renal agenesis there was an imperforate anus with rectovesical fistula, polysplenia and cerebellar hypoplasia. In cases 15 and 16 there was a large exomphalos and neural tube defect. In case 17, the mother had two previous terminations because the fetuses had cerebellar hypoplasia with flexion deformities of the wrists and talipes; in this pregnancy serial scans demonstrated development of talipes at 18 weeks and ventriculomegaly at 19 weeks. In case 18, there were abnormalities of the forearms and hands, and an autosomal dominant genetic condition was suspected, because identical findings were present in the brother of the pregnant woman. In case 19, the mother had a previous baby with multiple pterygium syndrome that died in the neonatal period. Recurrence of this condition was suspected, because in addition to the increased nuchal translucency there was fixed flexion deformity of the knees and elbows. In case 20, the fetus had a short neck and thorax, confirmed at postmortem examination, which also demonstrated fused ribs and wedge-shaped vertebrae. In case 21, there was discordancy in genetic and phenotype sex. Smith–Lemli–Opitz syndrome was diagnosed by biochemical analysis of skin fibroblasts[9].

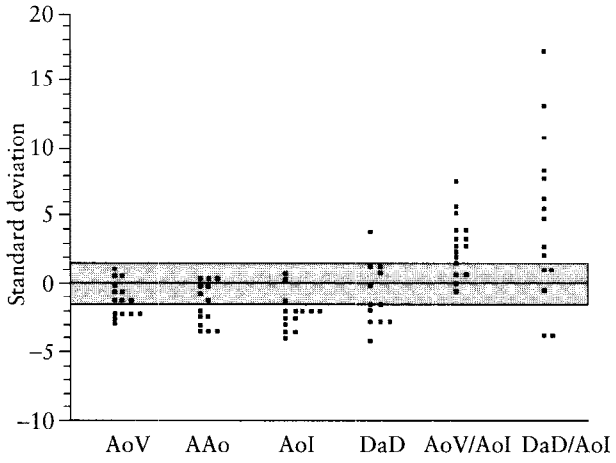


**Figure 4** Individual delta values for the aortic valve (AoV), ascending aorta (AAo), aortic isthmus (AoI), distal ductus arteriosus (DaD) and the ratios AoV to AoI and DaD to AoI. The three horizontal lines in the shaded area represent the 10th, 50th and 90th centiles

## DISCUSSION

This study has demonstrated that increased nuchal translucency thickness at 11–13 weeks of gestation in chromosomally normal fetuses is strongly associated with abnormalities of the heart and great arteries. Furthermore, in a large proportion of such fetuses, increased translucency may be a manifestation of an underlying genetic syndrome. In this respect, measurement of nuchal translucency thickness at 10–14 weeks may prove to be a useful method of screening for cardiac and other abnormalities in addition to its role in screening for chromosomal defects.

In this group of fetuses measurements of the great arteries demonstrated narrowing of the aortic isthmus and narrowing immediately above the aortic valve in proportion to the thickness of nuchal translucency. These findings are different from those associated with trisomy 21, where narrowing of the isthmus, found in 49% of the fetuses, was associated with widening of the aortic valve[6]. Since echocardiographic studies in trisomy 21 neonates found that the incidence of coarctation of the aorta was only 2.5%[10], we suggested that the high prevalence of narrowing of the isthmus in early pregnancy may be the consequence of developmental delay and that this feature disappears with advancing gestation[6]. In contrast, our finding in the chromosomally normal fetuses, that narrowing of the isthmus is accompanied by narrowing of the aortic valve and ascending aorta, is more consistent with the potential development of coarctation of the aorta.

Rudolph and Heymann[11] suggested that narrowing of the isthmus may be the developmental consequence of reduced blood flow into the ascending aorta. In 42 infants with coarctation of the aorta investigated by angiocardiography, they found that 56% had intracardiac lesions, and postulated that coarctation is the consequence of

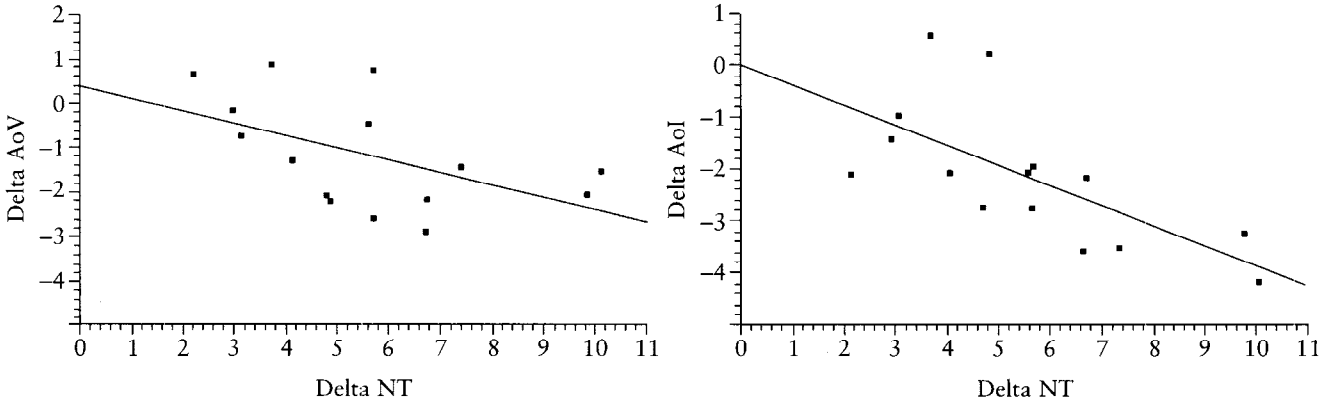


**Figure 5** Delta values for the aortic valve (AoV) and aortic isthmus (AoI) plotted against nuchal translucency (NT). The line of best fit is shown

hemodynamic alterations in flow through the great vessels. However, in our fetuses narrowing of the isthmus was not always associated with an intracardiac defect. Furthermore, the degree of narrowing of the aortic isthmus was greater than that of the aortic valve. Since blood flow is related to vessel diameter, it could be postulated that in these fetuses the proportion of left ventricular output that was diverted towards the head and neck was increased, with consequent congestion and development of nuchal edema. However, following the suggestion of Rudolph and Heymann[11], reduction of all diameters of the aorta, even with a disproportionate reduction in the isthmus, would not result in an overall increase of blood flow to the head and neck, but possibly a decrease. Furthermore, even if there is a regional increase in blood flow, this is unlikely to cause congestion and edema, unless there is simultaneous impairment in venous drainage.

An alternative explanation for the association between increased translucency and abnormalities of the heart and/or great arteries is heart failure, due to the potential strain that the abnormalities impose on cardiac function at a stage of pregnancy when a high proportion of cardiac output is normally diverted to the head and neck. Doppler studies have demonstrated that at 11–13 weeks of gestation impedance to flow in the intracerebral arteries is much lower than in the descending aorta[12]. Additionally, at 11–13 weeks impedance in the cerebral vessels is only marginally higher than in the late second trimester. In contrast, there is a major decrease in impedance in the descending aorta and umbilical arteries during the second trimester, thought to be the consequence of vascular changes in the placenta[12,13]. Supportive evidence for heart strain in fetuses with increased nuchal translucency is provided by the finding of increased cardiac mRNA expression of atrial natriuretic peptide and brain natriuretic peptide[14].

In the second trimester of pregnancy there is a well recognized association between cardiac defects and an abnormal accumulation of nuchal fluid, and such fluid accumulation is classified as cystic hygroma or nuchal edema[15–17]. A similar association between cardiac defects and abnormal nuchal fluid has been recognized in the first trimester. In a study of 114 pregnancies at high risk for cardiac defects, fetal echocardiography at 11–16 weeks correctly identified 12 of the 13 cases with cardiac defects and in ten of these cases there was abnormal collection of nuchal fluid[18]. In another series abnormal nuchal fluid was found in six of the eight fetuses with cardiac defects diagnosed by transvaginal sonography at 10–12 weeks of gestation[19].

In a screening study of 20 804 singleton pregnancies, ultrasound examination at 10–14 weeks of gestation demonstrated that the fetal nuchal translucency was at least 3 mm in 5% of the cases and the risk of chromosomal defects increased with translucency thickness[2]. The distribution of increased translucency in the chromosomally normal group is compared to that of the present study in Table 3. The translucency was 3 mm in 85.2% of the cases, whereas in our study population the translucency was 4 mm or more in 80% of the cases. It is therefore acknowledged that our population is not representative of all chromosomally normal fetuses with increased translucency.

**Table 3** Comparison of the distribution of nuchal translucency (NT) thickness of at least 3 mm in a screening study of 20 804 pregnancies[2] and in the present study

| | *Screening study* | | *Present study* | |
|---|---|---|---|---|
| *NT* (mm) | *n* | % | *n* | % |
| 3 | 886 | 85.2 | 4 | 20 |
| 4 | 108 | 10.3 | 1 | 5 |
| 5 | 27 | 2.6 | 6 | 30 |
| 6 | 12 | 1.2 | 3 | 15 |
| 7 | 1 | 0.1 | 1 | 5 |
| 8 | 4 | 0.4 | 1 | 5 |
| 9 | — | — | 1 | 5 |
| ≥ 10 | 2 | 0.2 | 3 | 15 |

A recent ultrasound screening study has reported that examination of the four-chamber view of the heart at 16–22 weeks of gestation can identify 26% of critical cardiac defects, defined as those requiring surgical repair; the prevalence of such defects was 3.5 per 1000 and in 18% of the cases there was trisomy 21 or 18[20]. In our study of 21 fetuses with increased nuchal translucency thickness at 11–13 weeks, critical cardiac defects were present in at least nine of the cases and eight of these were in the sub-group of 17 cases with translucency of 4 mm or more. Similarly, we have previously reported major abnormalities of the heart and great vessels in more than 75% of trisomy 21 and trisomy 18 fetuses with translucency thickness of 4 mm or more[3,4,6]. Therefore, irrespective of karyotype, the majority of fetuses with translucency of 4 mm or more may have a major abnormality of the heart and great arteries.

Since a translucency of 4 mm or more is found in about 1% of the population (Table 3)[2], it is tempting to suggest that the majority of major cardiac abnormalities present with increased nuchal translucency thickness at 10–14 weeks. If this proves to be true, then measurement of fetal nuchal translucency thickness at 10–14 weeks of gestation may prove to be the most sensitive method of screening for major abnormalities of the heart and great arteries. Alternatively, increased nuchal translucency preferentially identifies a sub-group of fetuses with cardiac defects that are destined to die *in utero* rather than potential live births. The value of screening for cardiac defects by measurement of nuchal translucency thickness at 10–14 weeks is now the subject of a multicenter study.

During the last 10 years many studies have reported the early sonographic features of a wide range of fetal abnormalities and genetic syndromes, but these studies were usually confined to high-risk populations, and no attempt was made to determine the sensitivity of ultrasound in the diagnosis of these abnormalities. The prevalence of various genetic syndromes, such as multiple pterygium syndrome. Jarco–Lavine syndrome and Smith–Lemli–Opitz syndrome is at most one per 20 000. Therefore, several thousands of patients need to be recruited in screening studies aiming to determine the sensitivity of the first-trimester scan in the

diagnosis of these conditions. In an ultrasound screening study at 10–14 weeks of gestation the prevalence of translucency of at least 5 mm in the chromosomally normal group was two per 1000[2]. This group included the three cases with the genetic syndromes of multiple pterygium, Jarco–Lavine syndrome and Smith–Lemli–Opitz syndrome and it is therefore possible that all such fetuses present with increased nuchal translucency thickness at 10–14 weeks.

## REFERENCES


1. Nicolaides, K. H., Azar, G., Byrne, D., Mansur, C. and Marks, K. (1992). Fetal nuchal translucency: ultrasound screening for chromosomal defects in first trimester of pregnancy. *Br. Med. J.*, **304**, 867–9
2. Pandya, P. P., Snijders, R. J. M., Johnson, S. P., Brizot, M. L. and Nicolaides, K. H. (1995). Screening for fetal trisomies by maternal age and fetal nuchal translucency thickness at 10–14 weeks of gestation. *Br. J. Obstet. Gynaecol.*, **12**, 957–62
3. Hyett, J. A., Moscoso, G. and Nicolaides, K. H. (1995). First trimester nuchal translucency and cardiac septal defects in fetuses with trisomy 21. *Am. J. Obstet. Gynecol.*, **172**, 1411–13
4. Hyett, J. A., Moscoso, G. and Nicolaides, K. H. (1995). Cardiac defects in first trimester fetuses with trisomy 18. *Fetal Diagn. Ther.*, **10**, 381–6
5. Hyett, J. A., Moscoso, G. and Nicolaides, K. H. (1995). Morphometric analysis of the great vessels in early fetal life. *Hum. Reprod.*, **10**, 3045–8
6. Hyett, J. A., Moscoso, G. and Nicolaides, K. H. (1995). Increased nuchal translucency in trisomy 21 fetuses: relation to narrowing of the aortic isthmus. *Hum. Reprod.*, **10**, 3049–51
7. Polkinghorne, J. (1989). *Review of the Guidance on the Research Use of Fetuses and Fetal Material*, Cm762. (London: Her Majesty's Stationery Office)
8. Pexider, T. and Janek, P. (1984). Organogenesis of the human embryonic and early fetal heart as studied by microdissection and SEM. In Nora, J. and Takao, A. (eds.) *Congenital Heart Disease, Causes and Processes*, pp. 401–22. (Mount Kisco: Futura Publishing)
9. Hyett, J. A., Clayton, P. T., Moscoso, G. and Nicolaides, K. H. (1995). Increased first trimester nuchal translucency as a prenatal manifestation of Smith–Lemli–Opitz syndrome. *Am. J. Med. Genet.*, **58**, 374–6
10. Tubman, T. R. J., Shields, M. D., Craig, B. G., Mulholland, H. C. and Nevin, N. C. (1991). Congenital heart disease in Down's syndrome: two year prospective early screening study. *Br. Med. J.*, **302**, 1425–7
11. Rudolph, A. M. and Heymann, M. A. (1976). Cardiac output in the fetal lamb: the effects of spontaneous and induced changes of heart rate on right and left ventricular output. *Am. J. Obstet. Gynecol.*, **124**, 183–92
12. Wladimiroff, J. W., Huisman, T. W. A. and Stewart, P. A. (1992). Intracerebral, aortic and umbilical artery flow velocity waveforms in the late first trimester fetus. *Am. J. Obstet. Gynecol.*, **166**, 46–9
13. Wladimiroff, J. W., Huisman, T. W. A. and Stewart, P. A. (1991). Fetal and umbilical flow velocity waveforms between 10–16 weeks' gestation: a preliminary study. *Obstet. Gynecol.*, **78**, 812–14
14. Hyett, J. A., Brizot, M. L., Von Kaisenburg, C., McKie, A. T., Farzaneh, F. and Nicolaides, K. H. (1996). Cardiac gene expression of atrial natriuretic peptide and brain natriuretic peptide in trisomic fetuses. *Obstet. Gynecol.*, in press
15. Nicolaides, K. H., Azar, G., Snijders, R. J. M. and Gosden, C. M. (1992). Fetal nuchal edema: associated malformations and chromosomal defects. *Fetal Diagn. Ther.*, **7**, 123–31
16. Azar, G. B., Snijders, R. J. M., Gosden, C. and Nicolaides, K. H. (1991). Fetal nuchal cystic hygromata: associated malformations and chromosomal defects. *Fetal Diagn. Ther.*, **6**, 46–57
17. DeVore, G. R. and Alfi, O. (1993). The association between an abnormal nuchal skin fold, trisomy 21, and ultrasound abnormalities identified during the second trimester of pregnancy. *Ultrasound Obstet. Gynecol.*, **3**, 387–94
18. Gembruch, U., Knopfle, G., Bald, R. and Hansmann, M. (1993). Early diagnosis of fetal congenital heart disease by transvaginal echocardiography. *Ultrasound Obstet. Gynecol.*, **3**, 310–17
19. Achiron, R., Rotstein, Z., Lipitz, S., Mashiach, S. and Hegesh, J. (1994). First-trimester diagnosis of fetal congenital heart disease by transvaginal ultrasonography. *Obstet. Gynecol.*, **84**, 69–72
20. Tegnander, E., Eik-Nes, S. H., Johansen, O. J. and Linker, D. T. (1995). Prenatal detection of heart defects at the routine fetal examination at 18 weeks in a non-selected population. *Ultrasound Obstet. Gynecol.*, **5**, 372–80